

Sophie Farooque

Key findings

- Anaphylaxis to Patent Blue dye was the fourth most common cause of perioperative anaphylaxis reported to NAP6.
- Nine cases of Patent Blue dye anaphylaxis were identified. This equates to an incidence of 14.6 per 100,000 administrations (1:6,863). This is higher than suxamethonium and one of the highest in NAP6 (second only to teicoplanin).
- None of the cases were fatal, but profound hypotension was common and six patients required transfer to critical care.
- Hypotension, laryngeal oedema, urticaria and cyanosis were the initial presenting features, and hypotension was universal during the event. Three patients had no skin signs at any point.
- In contrast to most perioperative anaphylaxis, there was sometimes a delay between the dye being injected and the onset of anaphylaxis.
- Surgery was completed in seven patients and abandoned in two. Delayed cases may need urgent advice or assessment by an allergy clinic to avoid undue delay in cancer surgery.
- All cases had positive skin prick tests to Patent Blue dye in the allergy clinic, and in one case both positive skin prick and intradermal tests.
- There was good correlation between anaesthetists' suspicion of Patent Blue anaphylaxis and confirmation by the allergy clinics and the NAP6 review panel.
- In several cases assumptions that an anaphylactic event after administration of Patent Blue dye had been caused by the dye led to failure to refer for investigation, or poor quality investigation in the allergy clinic.

What we know already

Since the 1960s, blue dyes have been recognised as a rare cause of anaphylaxis. The most widely used blue dye in Europe is Patent Blue (E131). Isosulfan blue is the disulfonated isomer of Patent Blue dye and is used in the USA (Pichler 2007). These two dyes have a high cross-reactivity, although Patent Blue is reported to be the less allergenic of the two (Barthelmes 2010). Methylene blue dye has no structural similarity, but cross-reactivity in those individuals allergic to Patent Blue dye has been described (Keller 2007).

The use of methylene blue in the UK has largely been superseded by Patent Blue because of concerns about the adequacy of lymphatic uptake and fat necrosis at the injection site. The mechanism of sensitisation to Patent Blue is uncertain, but it is highly water-soluble, is found in numerous everyday foods, and is used to colour medication and to dye clothing. It is thought likely that sensitisation occurs through contact with or consumption of everyday products containing E131, but this is uncertain. It is banned as a food dye in Australia, but many cases of suspected allergy are described in Australian breast cancer patients (Wong 2014).

One of the largest case series of patients with formally diagnosed anaphylaxis to Patent Blue dye was published in 2008 (Mertes 2008) and included 14 cases. Hypotension or cardiovascular collapse was the presenting feature in eleven cases, and skin signs were seen in eleven. There were no deaths, but the reactions were severe, with nine patients requiring prolonged intravenous adrenaline and transfer to critical care.

In Mertes' series, skin prick testing alone was found insufficient to confirm the diagnosis, and five patients also required intradermal testing. Conversely, a Norwegian series identified nine patients with hypersensitivity to Patent Blue dye over seven years and all were diagnosed on skin prick testing alone (Hunting 2010). In a UK series of six patients, skin prick testing was sufficient. This group also underwent intradermal testing, and all six patients had positive tests at 1:100 dilution (Haque 2010).

The diagnosis of anaphylaxis during anaesthesia can be difficult, with numerous differentials. When a drug is suspected of having triggered a reaction, the suspicion is usually based on a close temporal relationship between administration and the onset of symptoms. However allergic reactions caused by dyes can be delayed, possibly due to the kinetics of absorption from the subcutaneous tissue at the site of injection. In the Mertes series, the mean time from the injection of the dye to onset of symptoms was 30 minutes. In a French series of six patients with confirmed Patent Blue dye anaphylaxis, mean time to onset of anaphylaxis was 55 minutes (Brenet 2013).

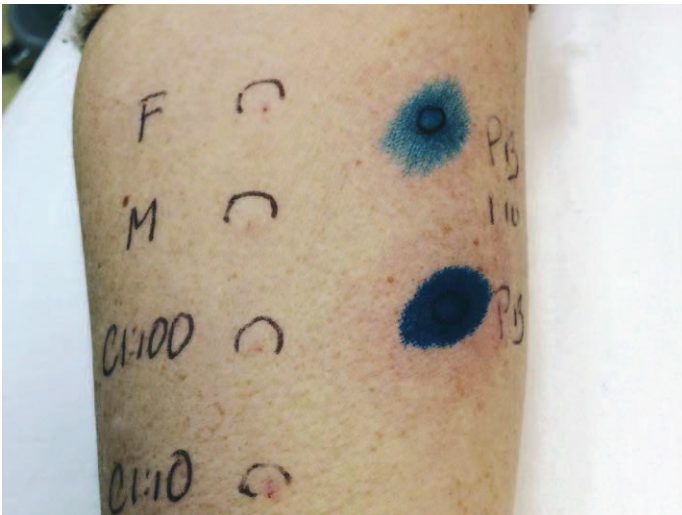
A further potential difficulty in the clinical diagnosis of anaphylaxis to Patent Blue dye is the interaction between the dye and pulse oximetry. This can lead to an artificial lowering in pulse oximetry values. Studies have identified relatively limited changes (mean 1.5%; standard deviation 1.8%) which may be slow in onset (mean time to the maximum change 30 minutes) (Mertes 2008). In another study, Patent Blue was confirmed not to decrease arterial blood oxyhaemoglobin saturation, but to impact on both digital and cerebral oximetry readings by 1.1% and 6.8%, ($p < 0.0001$ for both), with falsely reduced oximeter readings persisting for at least two hours (Ishiyama 2015). Importantly, however, the impact

on oximetry readings is variable between individuals, with some patients unaffected and others falling to saturations of 80%, and for prolonged periods (Murakami 2003, Takahashi 2013). Methylene Blue has been reported to do the same (Gorman 1988).

The reported incidence of allergy to Patent Blue dye varies considerably. In the larger case series, patients had not undergone formal allergy investigation and there was a reliance on the surgeon to make the diagnosis or to report reactions. Some series include all allergic reactions to Patent Blue dye and others anaphylaxis alone. Based on several retrospective and prospective studies, the estimated incidence of reactions of all grades of severity is 0.15–1.1%. A retrospective review of all suspected (unconfirmed) adverse reactions to Patent Blue dye in 7,917 patients after sentinel lymph node biopsy reported an incidence of Grade 1–4 hypersensitivity reactions of 0.85%, with no fatalities and a rate of 0.03% for severe reactions (Barthelmes 2010). A survey of 180 Australasian breast surgeons (with a 42% response rate) estimated an anaphylaxis rate of 0.15%, but only 24% of respondents had confirmed the diagnosis of anaphylaxis with allergy clinic investigation (Wong 2014). The largest case series in which hypersensitivity was confirmed by allergy clinic investigation reported an incidence of 0.34% (6 of 1,742 patients) (Brenet 2013). Other smaller equivalent case series reported incidences of 0.2–1.1% of cases (Mertes 2008, Hunting 2010).

Numerical analysis

Based on data from the Allergen Survey (Chapter 9), the incidence of anaphylaxis to Patent Blue is one case of anaphylaxis to Patent Blue in every 6,863 annual doses, that is 14.6 per 100,000 administrations.



Demographics and Clinical features

All patients were female.

Eight patients received Patent Blue dye to identify sentinel lymph node involvement in surgery for breast cancer, and one to assess fallopian tube patency. Five reactions were Grade 3 and four Grade 4. Six patients required critical care admission and three spent a prolonged period in recovery. In seven cases surgery was completed once the patient had stabilised, and in two it was abandoned.

Time between exposure to Patent Blue and onset of symptoms was variable and sometimes delayed – in seven cases less than 30 minutes and in two more than 60 minutes (Table 1). Interestingly, the patients with the greatest delay in onset were the two heaviest patients.

A patient was scheduled for elective breast surgery. Intraoperatively she developed a rash and received chlorphenamine and modest boluses of vasopressor. On arrival in recovery approximately two hours after induction, a rash and flushing was noted to be covering her whole body. She became bradycardic, profoundly hypotensive and hypoxic. A diagnosis of anaphylaxis was made and effective resuscitation was provided.

Hypotension was the most common presenting feature (four patients) and during the event all patients were hypotensive, with four having a systolic blood pressure below 50 mmHg. Six patients desaturated to less than 95%, four of these to less than 90%. Skin features (urticaria, angioedema, flushing) were seen in six patients, but three patients developed no cutaneous signs at all and urticaria was the presenting feature in only one patient. (Table 1). A fall in end-tidal carbon dioxide was reported in two cases.

Resuscitation

All cases were resuscitated successfully, and no long-term cardiovascular or cerebrovascular sequelae were reported. The review panel judged that the clinical management by the anaesthetist was 'good' in two cases, 'good and poor' in five, and 'poor' in two where adrenaline administration was delayed or absent (Table 2).

Resuscitation began within 5 minutes of the first sign of anaphylaxis in six cases. In one there was there a delay beyond 10 minutes.

Table 1. Clinical features at any time during Patent Blue anaphylaxis

Patient age (years - no. cases)	Time to onset (mins - no. cases)	Presenting feature (no. cases)	Lowest blood pressure (mmHg - no. cases)	Lowest oxygen saturation (% - no. cases)	Skin signs (no. cases)	Unplanned change in airway (no. cases)
26-45: 5	0-5: 2	Hypotension: 4	>90: 0	>95: 3	Urticaria: 3	Intubated: 4 No change: 5
46-65: 4	6-10: 2	Desaturation: 2	71-90: 2	90-94: 2	Angioedema: 4	
	10-15: 1	Urticaria: 1	50-70: 3	81-90: 2	Flushing: 4	
	16-30: 2	Tachycardia: 1	<50: 4	75-80: 2	Non-urticarial rash: 2	
	61-120: 2	Laryngeal oedema: 1			None: 3	

A woman undergoing elective sentinel lymph node biopsy received a Patent Blue dye injection shortly after induction of anaesthesia. She became hypotensive and required multiple bolus doses of ephedrine and then metaraminol throughout surgery. In recovery she was still hypotensive. She developed skin flushing, itching, oxygen desaturation and complained of feeling unwell. She was resuscitated with metaraminol boluses and large volumes of crystalloids. No adrenaline was administered.

In one case the patient was referred for evaluation of suspected anaphylaxis to methylene blue dye when they had in fact received Patent Blue dye.

A patient who received an antibiotic, skin preparation with chlorhexidine, and a Patent Blue dye injection developed skin flushing, hypotension, tachycardia, and oxygen desaturation. She was resuscitated uneventfully and her surgery was completed. She was not referred to an allergy clinic, but the anaesthetist diagnosed anaphylaxis to Patent Blue dye based on the timeline alone. She went on to have further surgery, receiving identical drugs with the exception of Patent Blue dye.

In four cases the patient's systolic blood pressure fell below 50 mmHg but chest compressions were not started. In three patients, tracheal intubation was performed as part of resuscitation.

Within five minutes of Patent Blue dye being injected, a patient developed laryngeal oedema, stridor, hypotension and mild desaturation. She was resuscitated with intramuscular adrenaline, chlorphenamine and hydrocortisone. A decision was made not to intubate. No airway complication occurred.

Investigation

All eight patients referred to an allergy clinic had a positive skin prick test to Patent Blue dye which confirmed the diagnosis. An intradermal test to Patent Blue dye was also performed in one case, and this was also positive. In one case skin prick testing to Patent Blue dye was the only investigation performed and no other drugs were investigated.

There was good correlation between the anaesthetists' opinions that Patent Blue dye had caused anaphylaxis and the findings of allergy clinics and the NAP6 review panel. Of the nine cases evaluated by the panel, eight patients were judged to have definitely reacted to Patent Blue dye and one to have probably reacted.

The review panel judged that investigation by the allergy clinic had been 'good' in four cases, 'good and poor' in two cases, 'poor' in one and was not assessed in one. The most common deviation from BSACI (British Society for Allergy and Clinical Immunology) guidelines was failure to investigate as culprits all drugs that the patient received in the hour prior to their anaphylaxis.

Time to clinic appointment and delays in surgery

The time before being seen at an allergy clinic appointment varied from 15 to 162 days. Reasons for prolonged waits were unknown, but it is noted elsewhere that urgent investigations were often delayed (see Chapter 14, Investigation). Despite some long waiting times, there was no evidence that urgent treatment had been delayed.

Discussion

Anaphylaxis to Patent Blue is a relatively common cause of perioperative anaphylaxis. Difficulty in recognising it may occur because:

- There may be delay in onset
- Falsely low peripheral oximetry readings may lead to distraction or mask true hypoxia associated with severe anaphylaxis
- Skin features may be absent.

Although no patient died, it should not be assumed that such reactions will be mild: many of the events were Grade 4 and required postoperative critical care. There was omission of cardiac compressions in the face of profound hypotension, and

Adrenaline was administered to seven of nine patients. In the cases where it was omitted, multiple doses of ephedrine, metaraminol, and in one case phenylephrine were used. All patients received intravenous crystalloid and eight patients received chlorphenamine and hydrocortisone.

Table 2. Initial management of Patent Blue dye anaphylaxis

Time to initiate treatment (minutes - no. cases)	Administration of adrenaline when Indicated	Adrenaline given IV	Adrenaline given IM	Anaesthetist management (panel rating)
0-5: 6	Yes: 7	Yes: 5	Yes: 2	Good: 2
6-10: 2	No: 2	No: 4	No: 7	Good and poor: 5
11-16: 1				Poor: 2

Tryptase

Mast cell tryptase levels were available for eight cases. In six of these a dynamic MCT was seen (highest level - 72.7 mcg/L), in one case there was no rise, and in one case levels were elevated both at baseline and during anaphylaxis suggesting that the patient had an underlying mast cell disorder.

Referral

Referrals to the allergy clinic were mostly made by the index anaesthetist and were 'good', with the exception of one case which was not referred at all for further investigation. This decision appeared to be made on the basis of the urgency of cancer treatment, and in a subsequent anaesthetic the patient received identical drugs with the exception of omission of Patent Blue dye.

not all patients received timely adrenaline. These findings are not restricted to the management of Patent Blue anaphylaxis and are discussed in Chapter 12, Deaths, cardiac arrest, and profound hypotension, and Chapter 11, Immediate management and departmental organisation, respectively.

Peripheral oxygen concentrations can be low after administration of Patent Blue dye without hypoxia or anaphylaxis, but the impact of Patent Blue on oxygen saturations is variable. This might lead anaesthetists to assume that apparent hypoxia is artefactual, or may delay diagnosis of anaphylaxis or other acute conditions. Great caution is required when there is apparent hypoxia, and management should proceed with the presumption that the measurement is correct. A change in airway device (intubation during resuscitation) was more common during Patent Blue dye anaphylaxis than in other cases. This may be a consequence of concerns about difficulty in interpreting oximetry readings, and it is a welcome finding that there were no airway complications. The low rate of airway difficulty or complications in NAP6 is discussed in Chapter 11, Immediate management and departmental organisation.

Most cases occurred during surgery for breast cancer, and all occurred after surgery had started. Many reactions were severe, but no patient developed cardiac arrest or died. In this situation, it may be difficult to decide whether to complete the surgery (which is often less major than other cancer operations) or to abandon it. In general, judgement seemed to have been good. Where surgery is abandoned an individual decision will need to be made regarding future options. Allergy clinic appointments at less than six weeks may lead to incomplete investigation, or false negative results. Options therefore include urgent allergy clinic assessment, proceeding with surgery before allergy clinic investigation (see Chapter 11, Appendix C), or non-operative treatments. Where urgent clinic assessment is desirable or surgery is to take place without full assessment, urgent discussion with the allergy clinic is likely to be useful, and improved routes of communication between departments of anaesthesia and specialist allergy clinics are likely to facilitate this (see Chapter 11, Immediate management and departmental organisation).

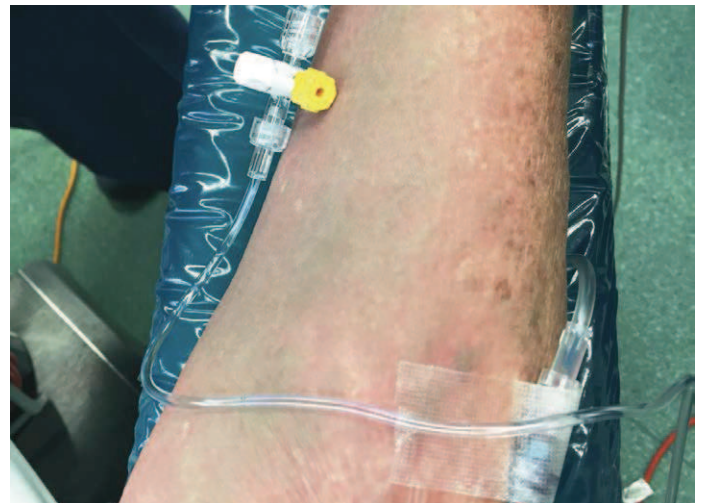Anaesthetists were generally correct when they suspected Patent Blue dye as a cause of perioperative anaphylaxis. However, there is a danger of confirmation bias. It was of concern that one patient

was simply assumed to have reacted to Patent Blue dye when other potential culprits had also been administered, and the panel judged that allergy clinic referral should take place after all such events. In another case, the allergy clinic only tested for allergy to Patent Blue dye and ignored all other drugs, and in other cases after exposure to Patent Blue dye there was an incomplete search for other culprits. All drugs that the patient received should be investigated during the patient's allergy clinic investigations. Skin testing for the key suspect drugs is not sufficient. In all these there was the potential that another cause of anaphylaxis might have been missed with the potential for harm to the patient.

Recommendations

Individual

- If administration of Patent Blue dye is planned during surgery, the surgical team should discuss the risk of anaphylaxis as part of the consent process for surgery
- If anaphylaxis occurs in a patient who has received Patent Blue dye, it should not be assumed that this is the culprit, and the patient should be referred for specialist allergy investigation
- Where pulse oximeter saturations fall during anaphylaxis in a patient who has received Patent Blue dye, hypoxia should be assumed to be real. A blood gas sample should be taken, when the patient is stable enough for this.



References

- Barthelmes 2010: Barthelmes L, Goyal A, Newcombe RG, McNeill F, Mansel RE; NEW START and ALMANAC study groups. Adverse reactions to patent blue V dye - The NEW START and ALMANAC experience. *Eur J Surg Oncol.* 2010; 36: 399-403.
- Brenet 2013: Brenet O, Lalourcey L, Queinnec M *et al.*, Hypersensitivity reactions to Patent Blue V in breast cancer surgery: a prospective multicentre study. *Acta Anaesthesiol Scand.* 2013; 57: 106-11.
- Gorman 1988: Gorman ES, Shnider MR. Effect of methylene blue on the absorbance of solutions of haemoglobin. *Br J Anaesth.* 1988; 60: 439-44.
- Haque 2010: Haque RA, Wagner A, Whisken JA, Nasser SM, Ewan PW. Anaphylaxis to Patent Blue V: a case series and proposed diagnostic protocol. *Allergy.* 2010; 65: 396-400.
- Hunting 2010: Hunting AS, Nopp A, Johansson SG, Andersen F, Wilhelmsen V, Guttormsen AB. Anaphylaxis to Patent Blue V. Clinical aspects. *Allergy.* 2010; 65: 117-23.
- Ishiyama 2015: Ishiyama T, Kotoda M, Asano N *et al.* The effects of Patent Blue dye on peripheral and cerebral oxyhaemoglobin saturations. *Anaesthesia.* 2015; 70: 429-33.
- Keller 2007: Keller B, Yawalkar N, Pichler C, Braathen LR, Hunger RE. Hypersensitivity reaction against Patent Blue during sentinel lymph node removal in three melanoma patients. *Am J Surg.* 2007; 193: 122-4.
- Mertes 2008: Mertes PM, Malinovsky JM, Mouton-Faivre C *et al.* Anaphylaxis to dyes during the perioperative period: reports of 14 clinical cases. *J Allergy Clin Immunol.* 2008; 122: 348-52.
- Murakami 2003: Murakami T, Kayo R, Kajita I, Cho S SH. False decrease in pulse oximetry readings due to Patent Blue in a patient with breast cancer. *Masui* 2003; 52: 909-11.
- Pichler 2007: Drug Hypersensitivity in Drug Hypersensitivity; Editor Pichler WJ. Published by Karger 2007. ISBN: 978-3-8055-8269-8.
- Takahashi 2013: Takahashi Y, Hara K ST. A case of prolonged reduction in arterial oxygen saturation measured by pulse oxymetry after administering patent blue in an elderly patient. *Masui* 2013; 62: 422-4.
- Wong 2014: Wong A, Spillane A, Breast Surgeons of Australia and New Zealand Incorporated Patent Blue V dye anaphylaxis: experience of Australian and New Zealand surgeons. *ANZ J Surg.* 2014; 84: 37-41.