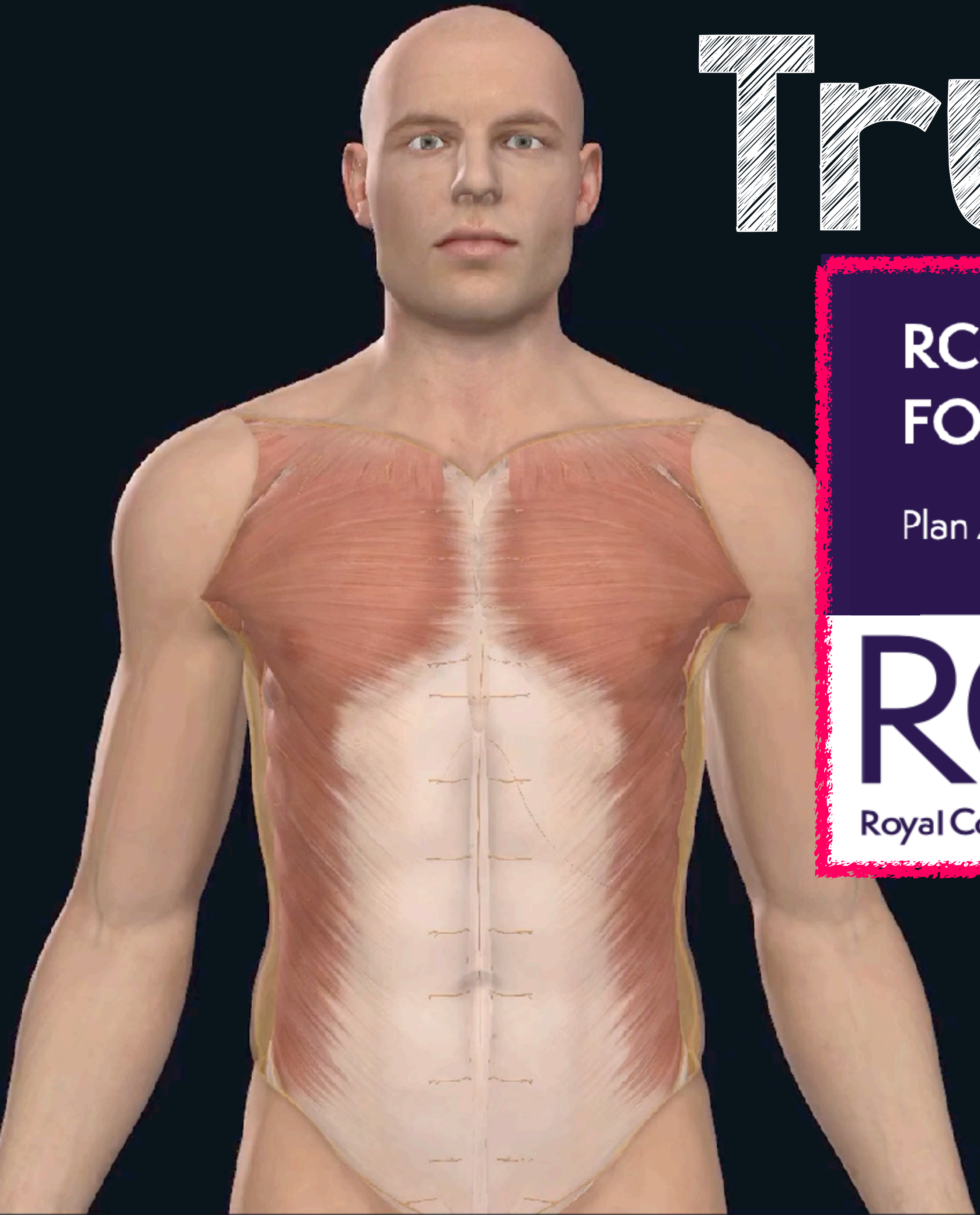



# Trunk Blocks

RCoA and RA-UK joint webinar: **BLOCKS FOR THE MANY** (not just the few)

Plan A blocks for simplicity, safety and efficacy

**RCoA**  
Royal College of Anaesthetists



**RA-UK**  
Regional Anaesthesia United Kingdom

**Dr Amit Pawa**

**@amit\_pawa**

**#PlanABlocks**



Bridge Consulting Rooms

St Thomas' Hospital

# Disclosures

**RA-UK President**



**Honoraria:**

**GE Healthcare**

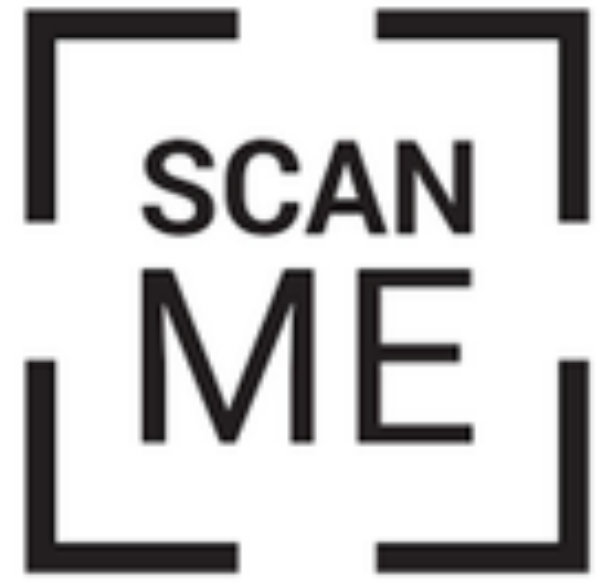**Sintetica Ltd**

**Consultation:**

**B Braun Medical Ltd**

**Complete Anatomy App 3D4 Medical**

**@amit\_pawa**



Editorial

**Future directions in regional anaesthesia: not just for the cognoscenti**

L. R. Turbitt,<sup>1</sup> E. R. Mariano<sup>2</sup> and K. El-Boghdadly<sup>3</sup>

**Promote competence  
in a few HIGH VALUE  
“Plan A” Blocks  
Increase Patient  
access to RA**



@amit\_pawa

Anatomical Location	Plan A Block
Shoulder	Interscalene
Upper limb below Shoulder	Axillary
Hip	Femoral Nerve
Knee	Adductor Canal
Foot & Ankle	Popliteal Sciatic
Chest Wall	Erector Spinae Plane
Abdominal Midline	Rectus Sheath



Editorial

# Future directions in regional anaesthesia: not just for the cognoscenti

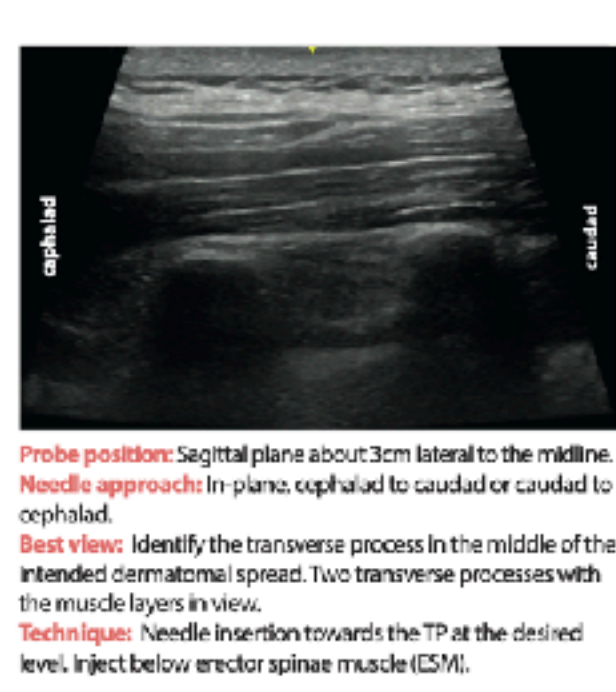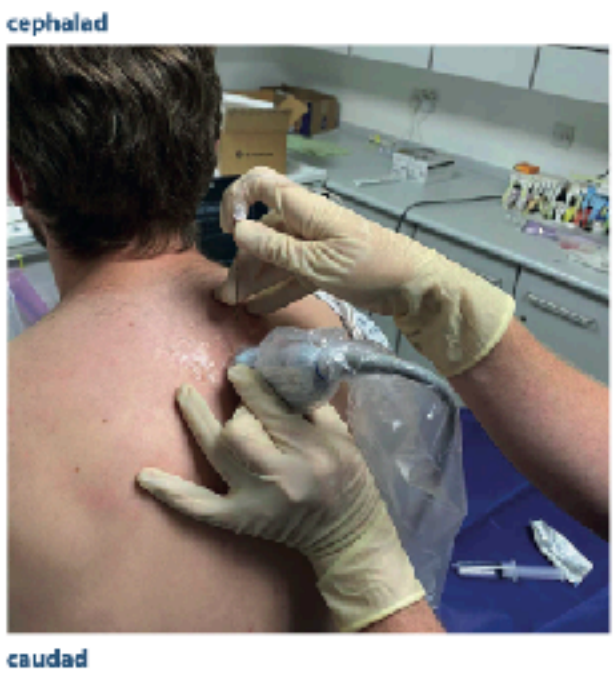L. R. Turbitt,<sup>1</sup> E. R. Mariano<sup>2</sup> and K. El-Boghdadly<sup>3</sup>

Promote competence  
in a few HIGH VALUE  
"Plan A" Blocks  
Increase Patient  
access to RA



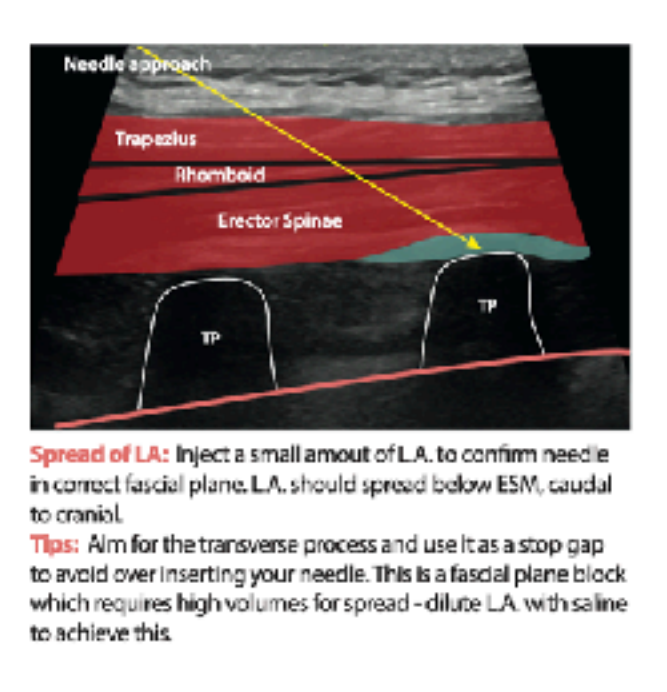
@amit\_pawa

## Chest Wall



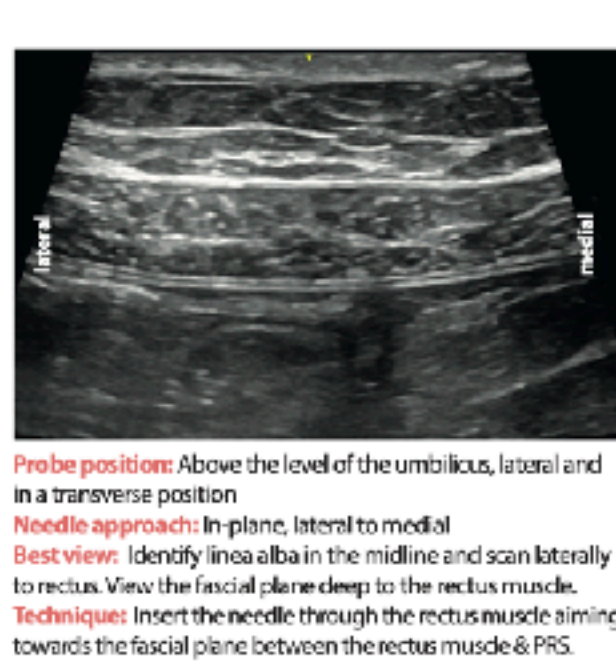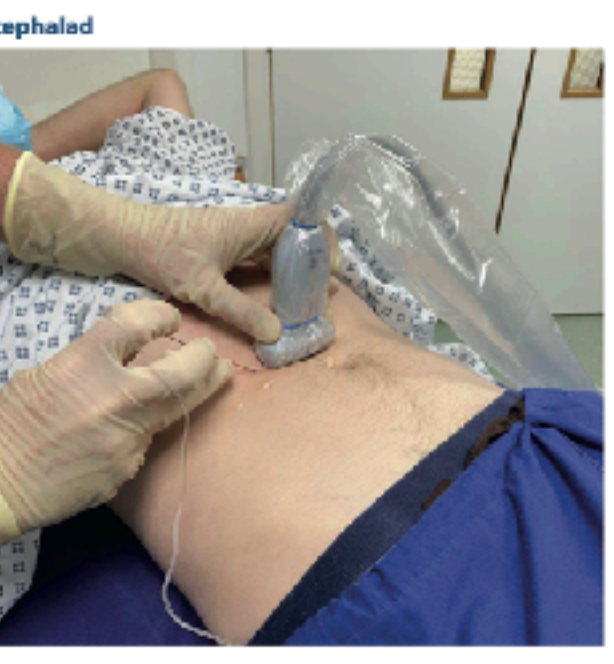**Probe position:** Sagittal plane about 3cm lateral to the midline.  
**Needle approach:** In-plane, cephalad to caudad or caudad to cephalad.  
**Best view:** Identify the transverse process in the middle of the intended dermatomal spread. Two transverse processes with the muscle layers in view.  
**Technique:** Needle insertion towards the TP at the desired level. Inject below erector spinae muscle (ESM).

## Erector Spinae Plane



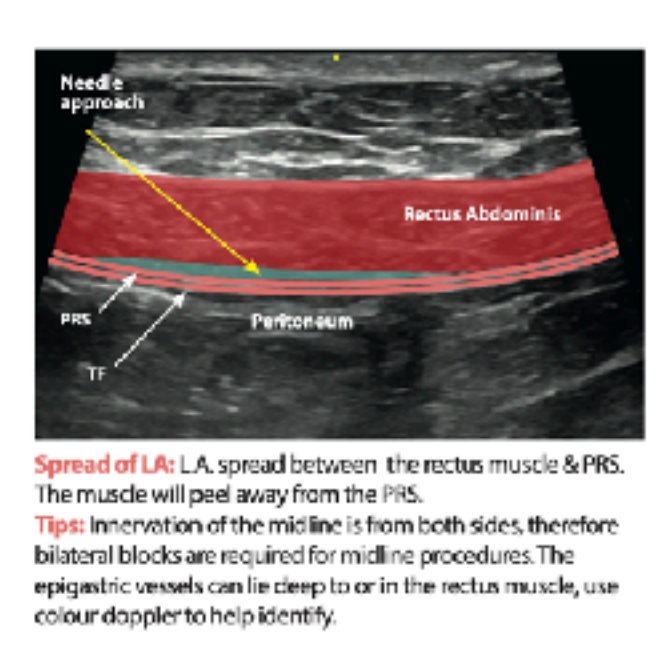
**Spread of LA:** Inject a small amount of LA, to confirm needle in correct fascial plane. LA should spread below ESM, caudad to cranial.  
**Tips:** Aim for the transverse process and use it as a stop gap to avoid over inserting your needle. This is a fascial plane block which requires high volumes for spread - dilute LA with saline to achieve this.

## Abdominal Midline



**Probe position:** Above the level of the umbilicus, lateral and in a transverse position.  
**Needle approach:** In-plane, lateral to medial.  
**Best view:** Identify linea alba in the midline and scan laterally to rectus. View the fascial plane deep to the rectus muscle.  
**Technique:** Insert the needle through the rectus muscle aiming towards the fascial plane between the rectus muscle & PRS.

## Rectus Sheath



**Spread of LA:** LA spread between the rectus muscle & PRS. The muscle will peel away from the PRS.  
**Tips:** Innervation of the midline is from both sides, therefore bilateral blocks are required for midline procedures. The epigastric vessels can lie deep to or in the rectus muscle, use colour doppler to help identify.

# RA-UK Plan A Block Posters coming soon!

Thanks to:  
 @ann\_barroni  
 @drstu\_wade  
 @c\_johnstone1980

@amit\_pawa

## RA-UK UPPER LIMB & TRUNK PLAN A BLOCKS

	PROBE POSITION	ULTRASOUND IMAGE	ULTRASOUND ANATOMY
<b>INTERSCALENE BRACHIAL PLEXUS BLOCK</b> Indications: Shoulder procedures Positioning: Supine, head turned to contralateral side Depth: 4-6cm Needle: 20G-22G Volume: 15-20ml Abbr: Interscalene Block N1 - Middle Scapular Nerve N2 - Axillary Scapular Nerve N3 - Spinal Accessory Nerve N4 - Cervical Plexus N5 - Brachial Plexus			
<b>AXILLARY BRACHIAL PLEXUS BLOCK</b> Indications: Forearm and hand procedures Positioning: Supine, arm abducted and extended Depth: 4-6cm Needle: 20G-22G Volume: 15-20ml Abbr: Axillary Block N1 - Axillary Nerve N2 - Brachial Plexus N3 - Radial Nerve N4 - Median Nerve N5 - Ulnar Nerve			
<b>ERECTOR SPINAE PLANE BLOCK</b> Indications: Cervical and thoracic procedures Positioning: Prone, arms extended Depth: 4-10cm Needle: 20G-22G Volume: 20-30ml Abbr: Erector Spinae Block N1 - Cervical Plexus			
<b>RECTUS SHEATH BLOCK</b> Indications: Midline abdominal procedures Positioning: Supine Depth: 4-6cm Needle: 20G-22G Volume: 20-30ml Abbr: Rectus Sheath Block N1 - T10-T12			

## RA-UK LOWER LIMB PLAN A BLOCKS

	PROBE POSITION	ULTRASOUND IMAGE	ULTRASOUND ANATOMY
<b>FEMORAL NERVE BLOCK</b> Indications: Hip procedures Positioning: Supine, hip slightly abducted Depth: 4-6cm Needle: 20G-22G Volume: 15-20ml Abbr: Femoral Block N1 - Femoral Nerve N2 - Femoral Sheath N3 - Femoral Vein			
<b>ADDUCTOR CANAL BLOCK</b> Indications: Knee procedures Positioning: Supine, knee flexed Depth: 4-6cm Needle: 20G-22G Volume: 15-20ml Abbr: Adductor Canal Block N1 - Tibial Nerve N2 - Saphenous Nerve N3 - Femoral Nerve			
<b>POPLITEAL SCIATIC BLOCK</b> Indications: Fore and ankle procedures Positioning: Supine, knee flexed Depth: 4-6cm Needle: 20G-22G Volume: 20ml Abbr: Popliteal Block N1 - Tibial Nerve N2 - Saphenous Nerve N3 - Femoral Nerve N4 - Sciatic Nerve			
<b>ERGONOMICS</b> Indications: Prolonged standing procedures Positioning: Supine Depth: 4-6cm Needle: 20G-22G Volume: 20ml Abbr: Ergonomics Block N1 - Tibial Nerve N2 - Saphenous Nerve N3 - Femoral Nerve			

**Indications, Anatomy, Technique**

**Rectus Sheath Block**

**Erector Spinae Plane Block**

# Rectus Sheath Block



Simple



Safe



Versatile



Effective

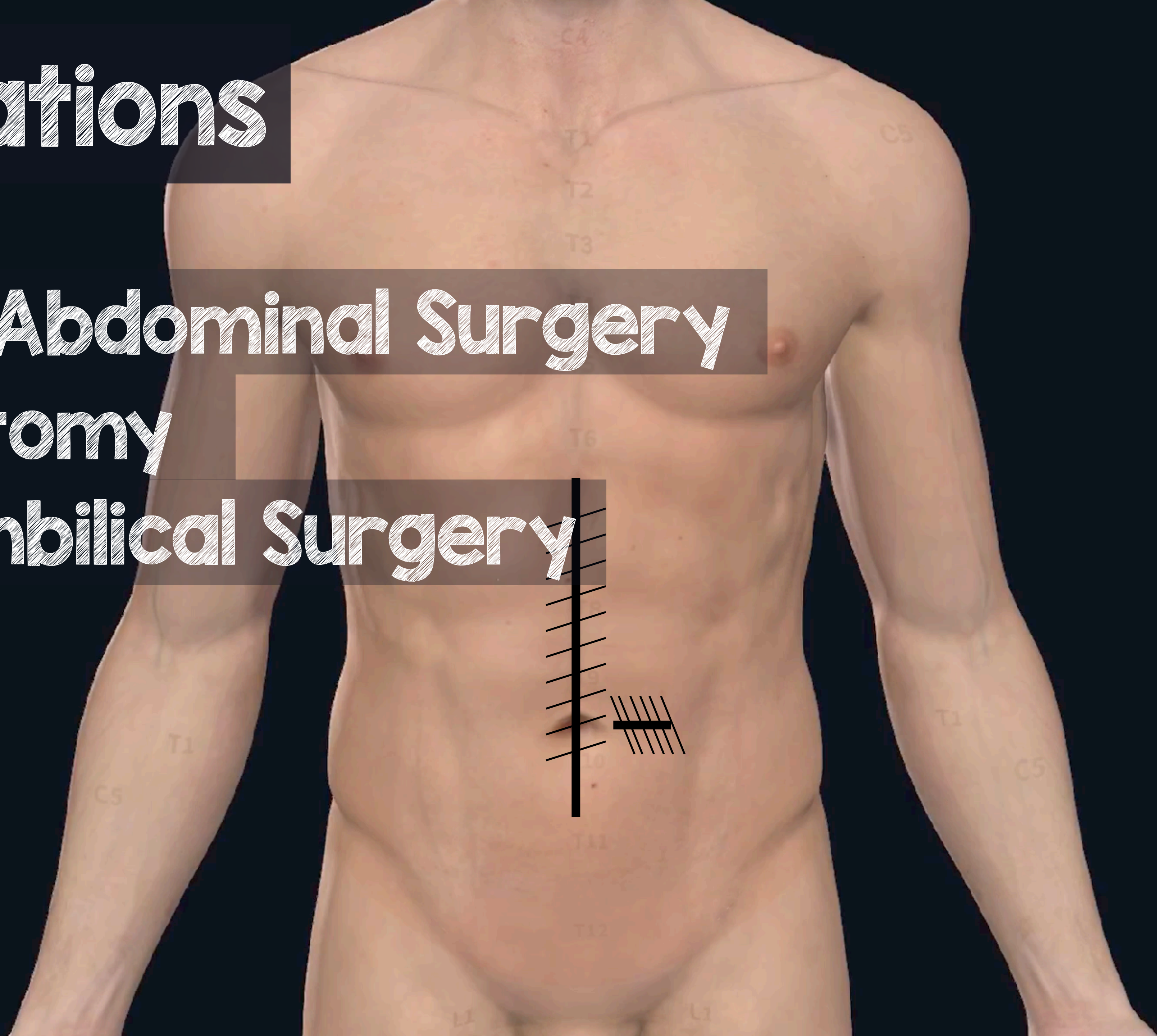


# Indications

Midline Abdominal Surgery

Laparotomy

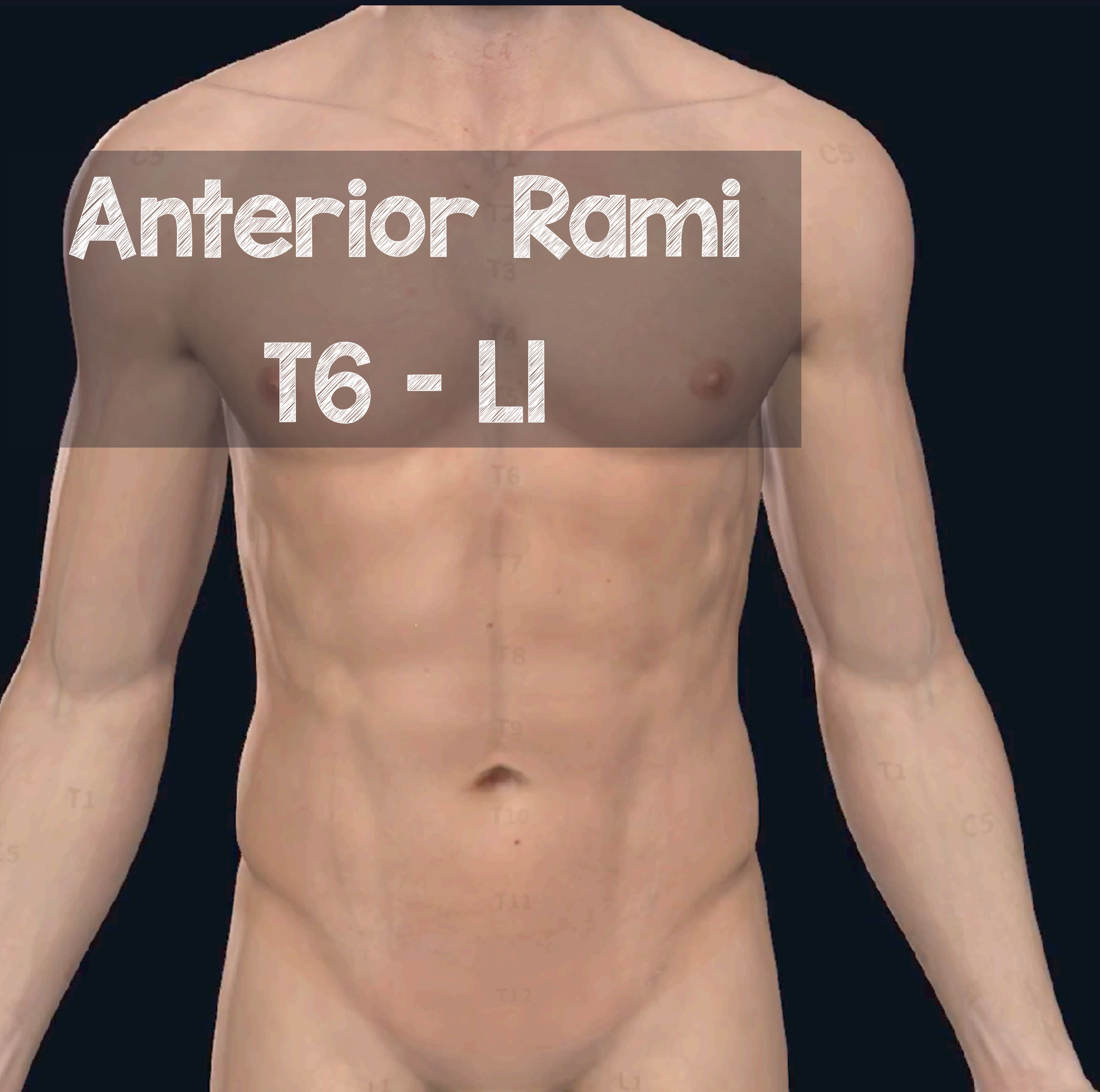
Para-umbilical Surgery



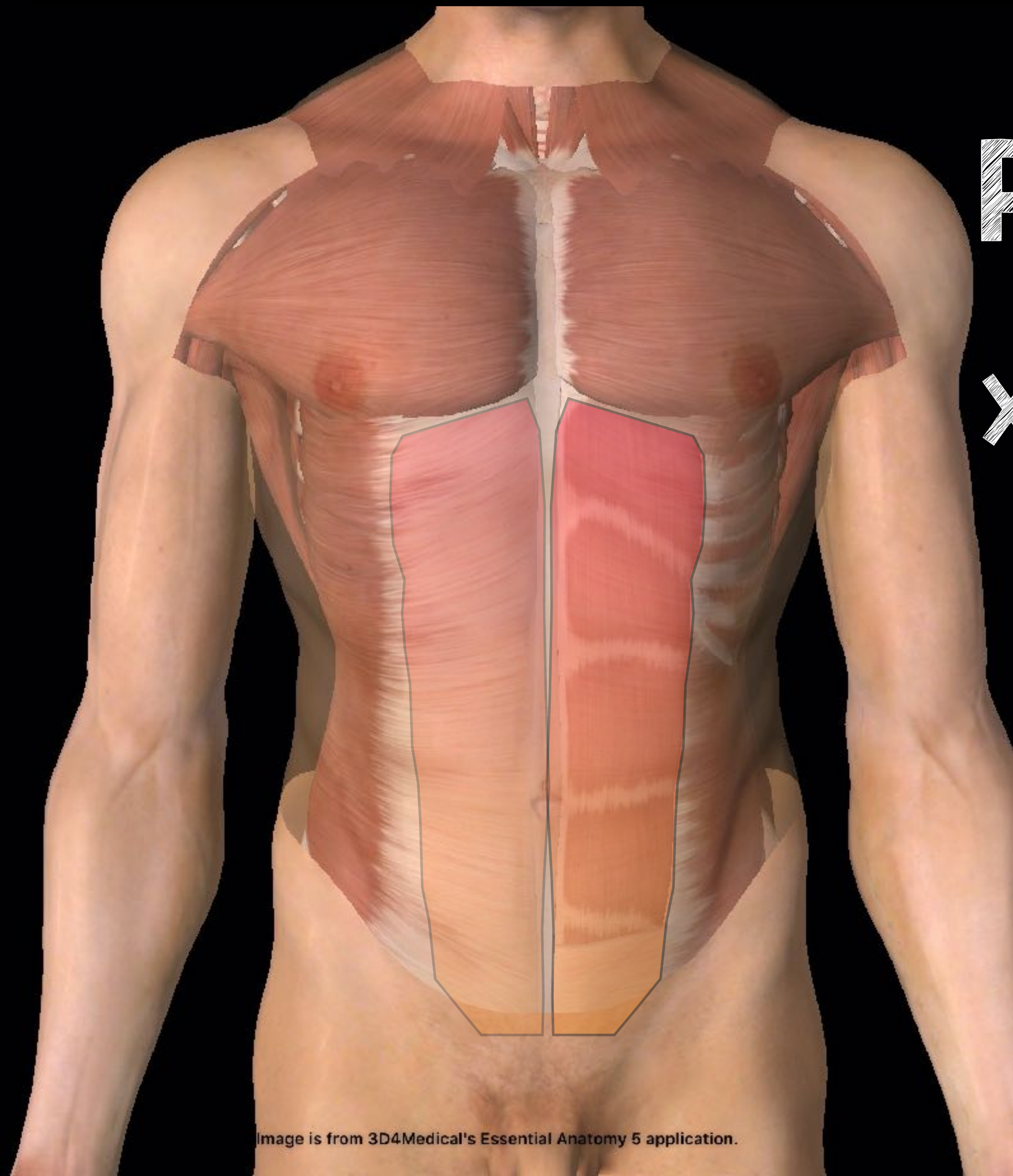
# Anatomy: Rectus Abdominis

Anterior Rami

T6 - L1



# Anatomy: Rectus Abdominis



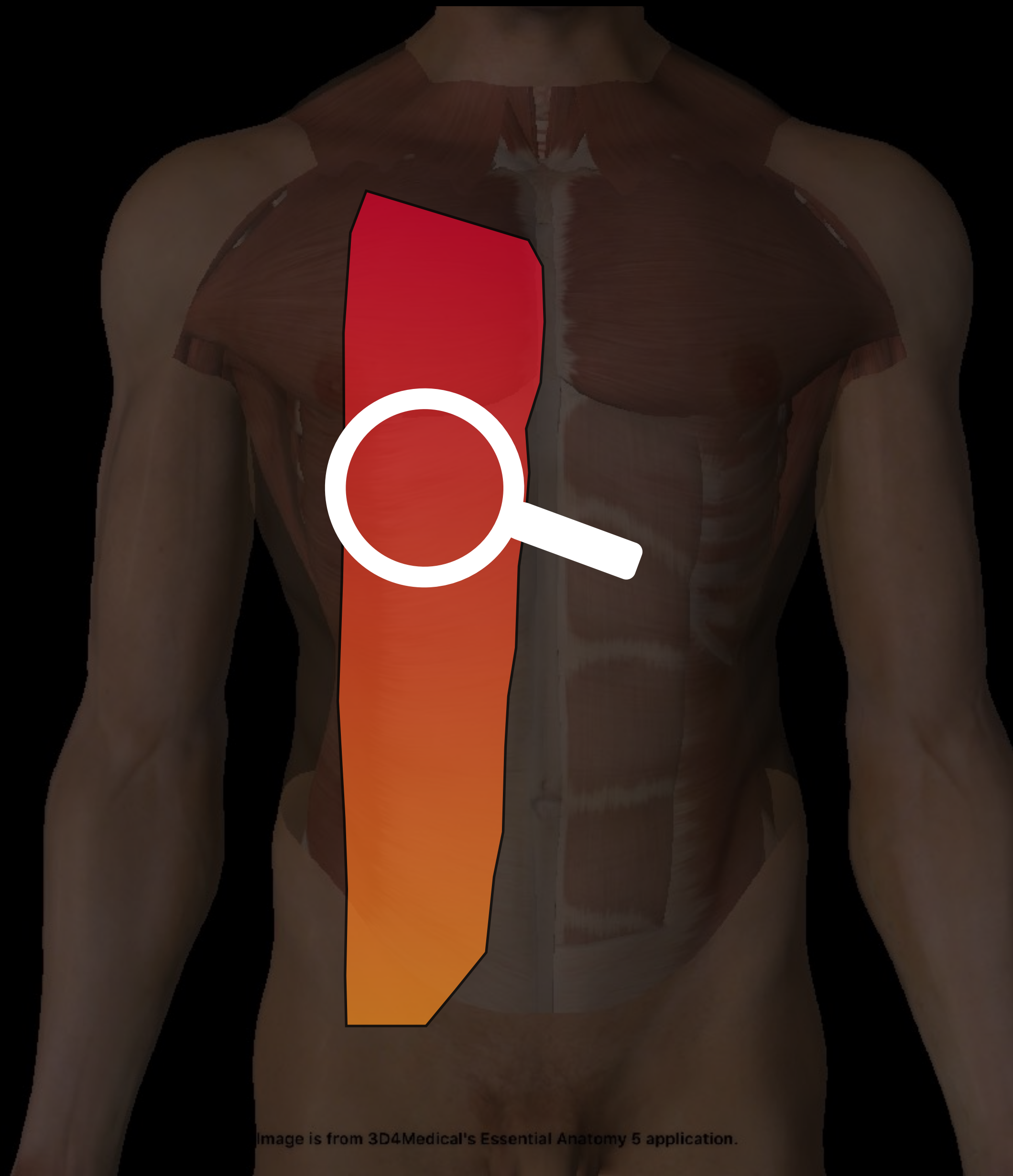
**Paired Midline Muscle**

**Xiphoid & Costal cartilages**



**Pubic Symphysis & Pubic Crest**

# Anatomy: Rectus Abdominis



# Anatomy: Rectus Abdominis

Anterior Rectus Sheath

Posterior Rectus Sheath

Rectus Abdominis

Transversalis Fascia

Peritoneum

External Oblique

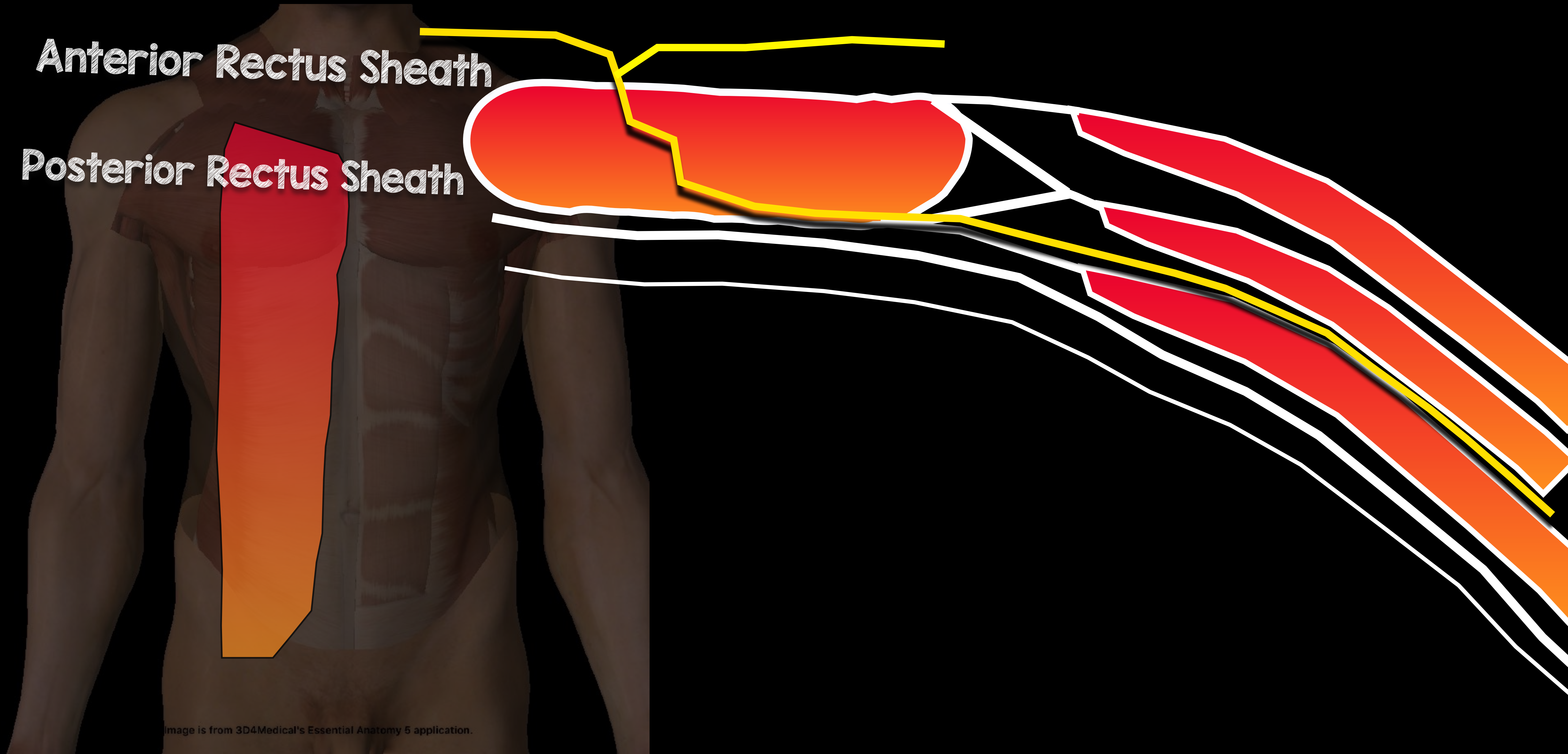
Internal Oblique

Transversus Abdominis

# Anatomy: Rectus Abdominis

Anterior Rectus Sheath

Posterior Rectus Sheath

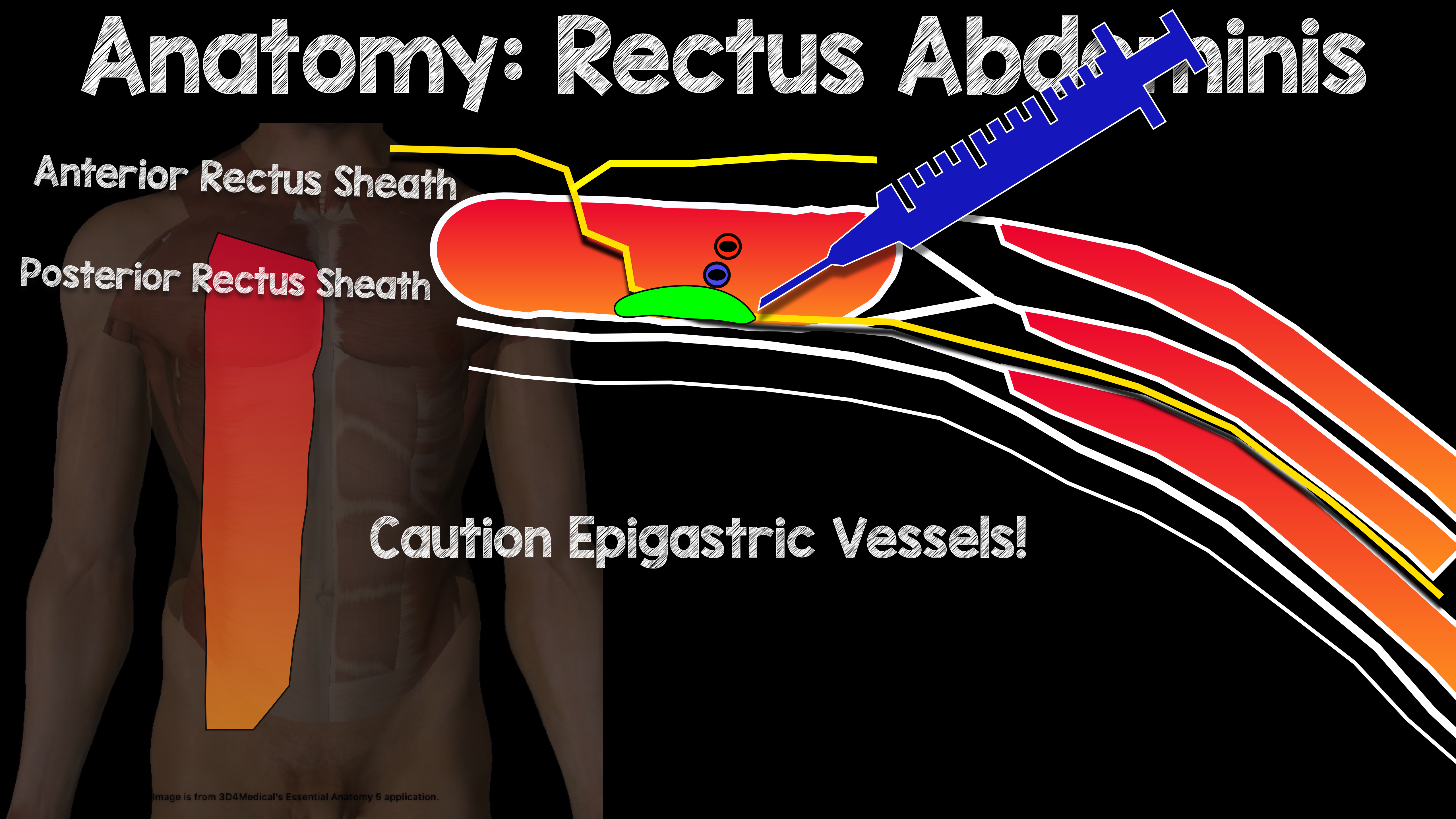


# Anatomy: Rectus Abdominis

Anterior Rectus Sheath

Posterior Rectus Sheath

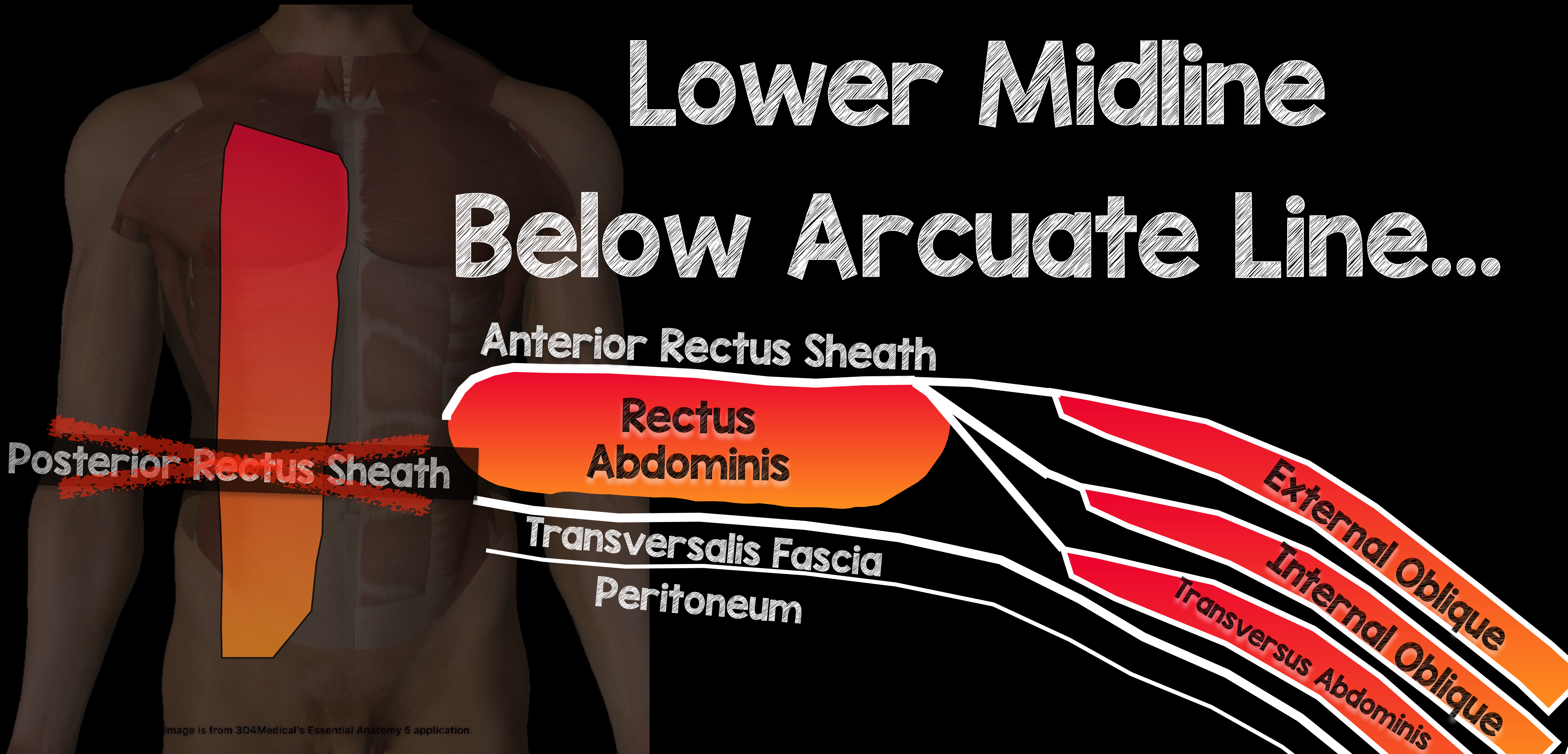
Caution Epigastric Vessels!



# Anatomy: Rectus Abdominis

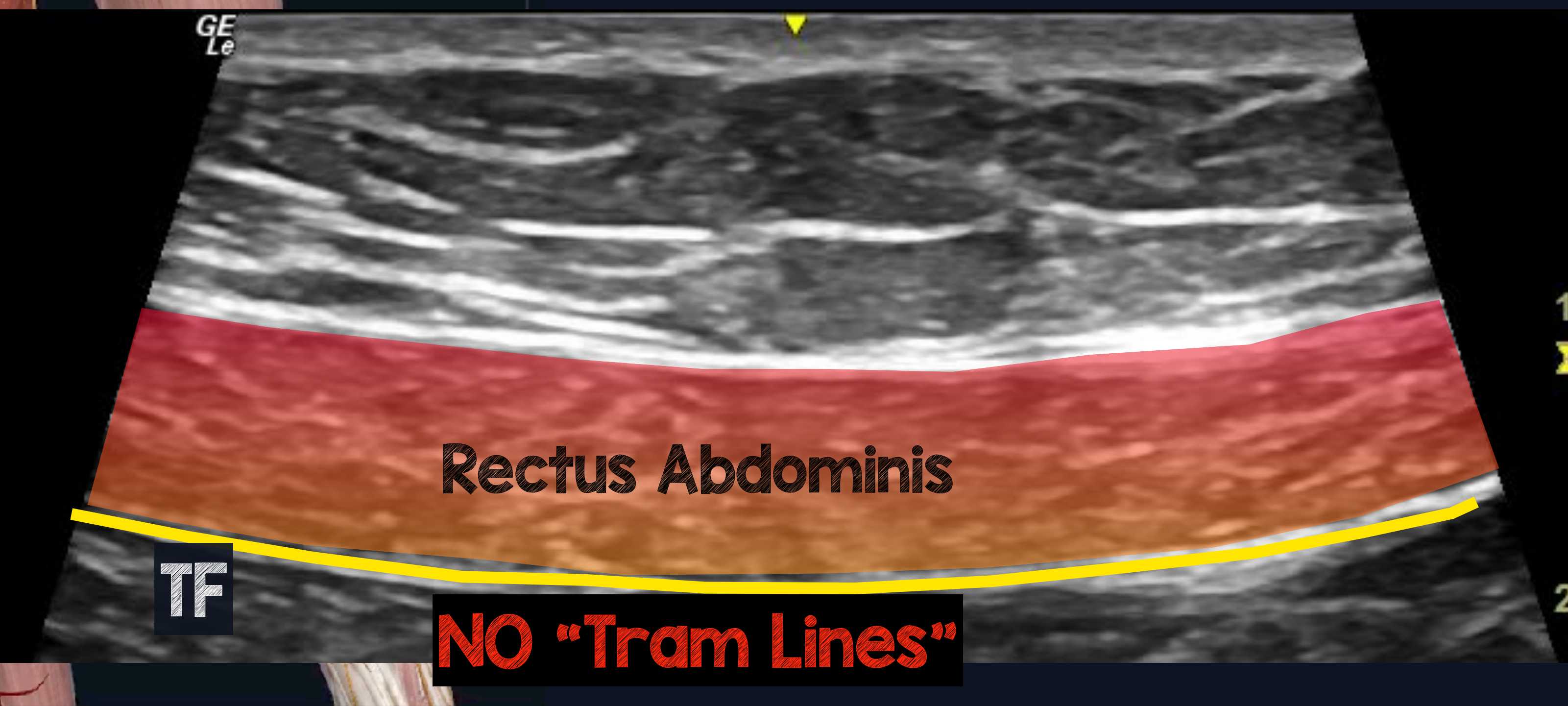
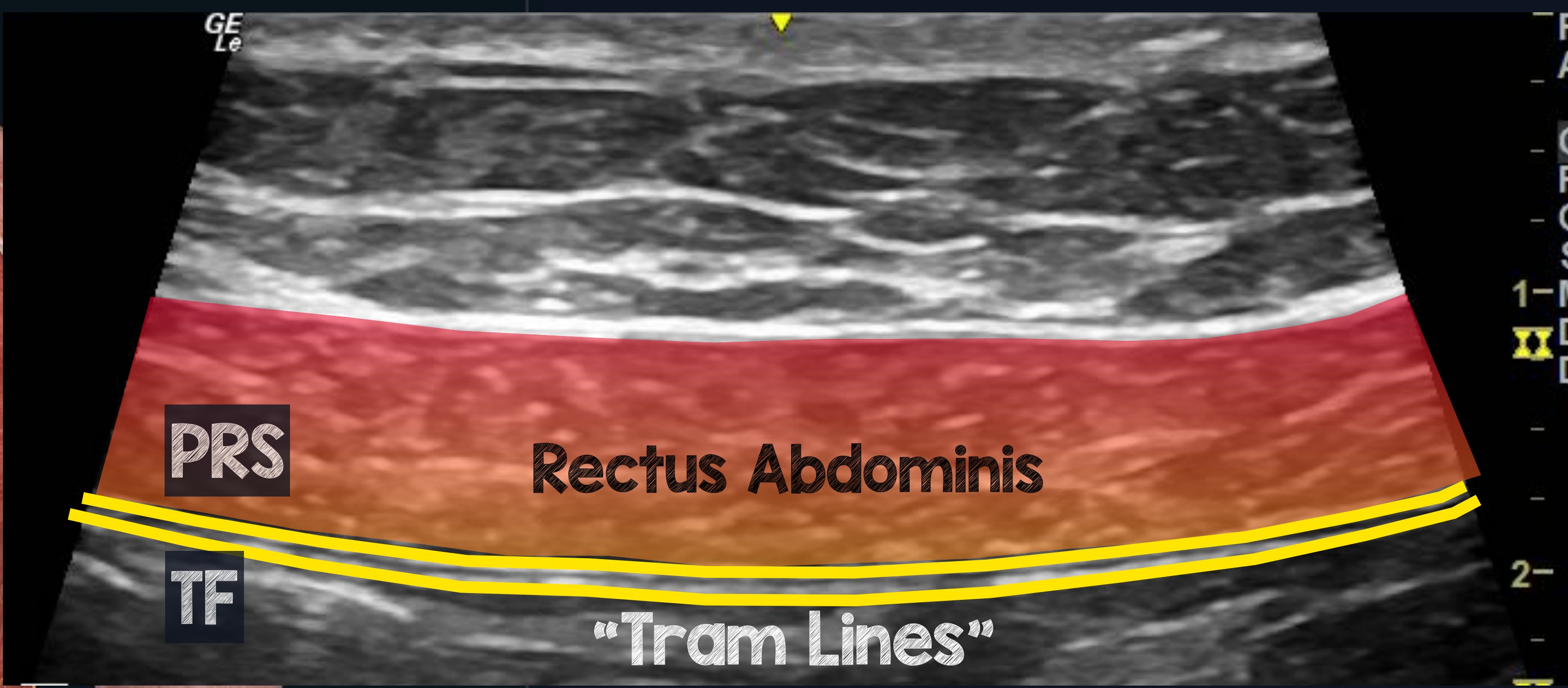
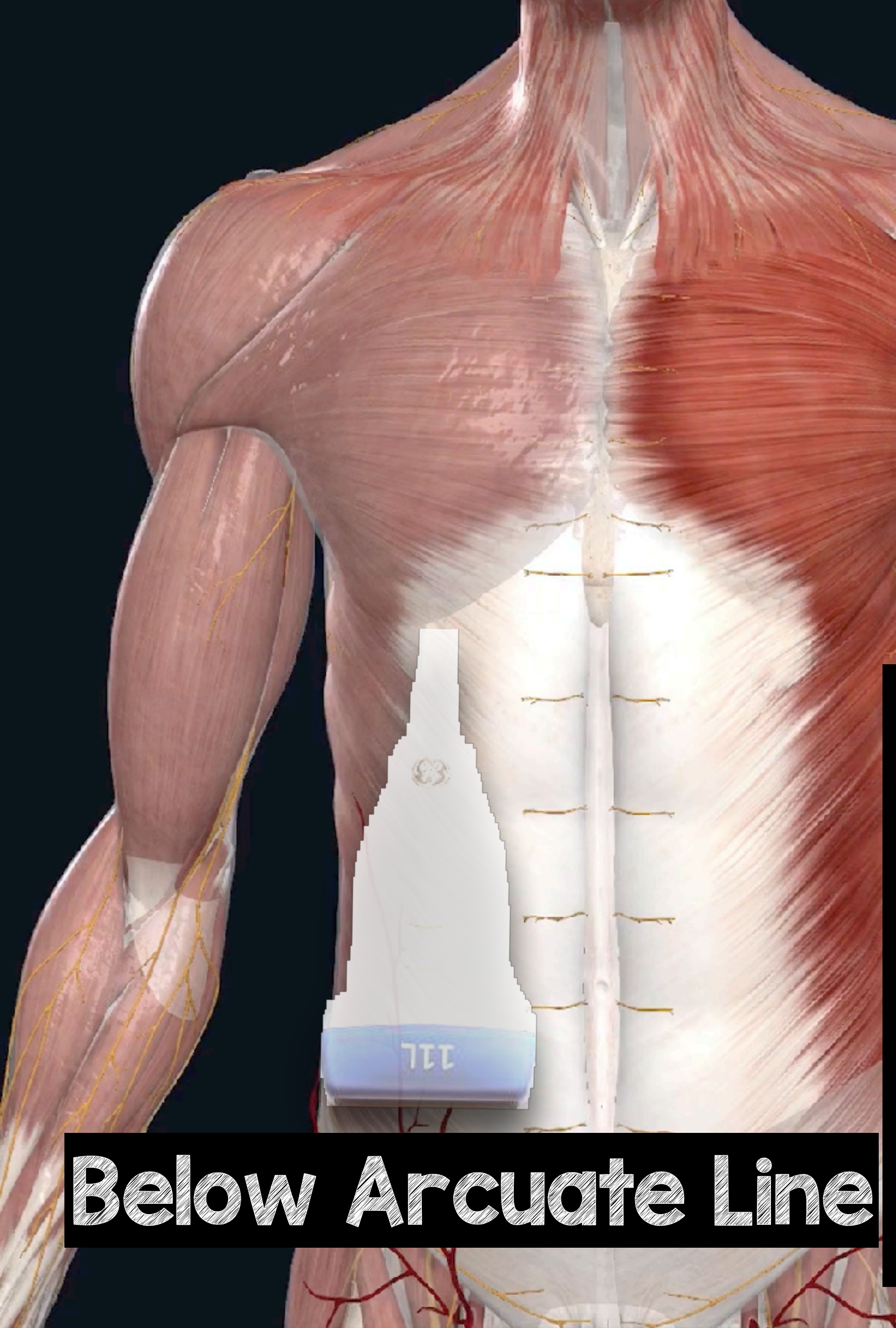## Lower Midline

## Below Arcuate Line...

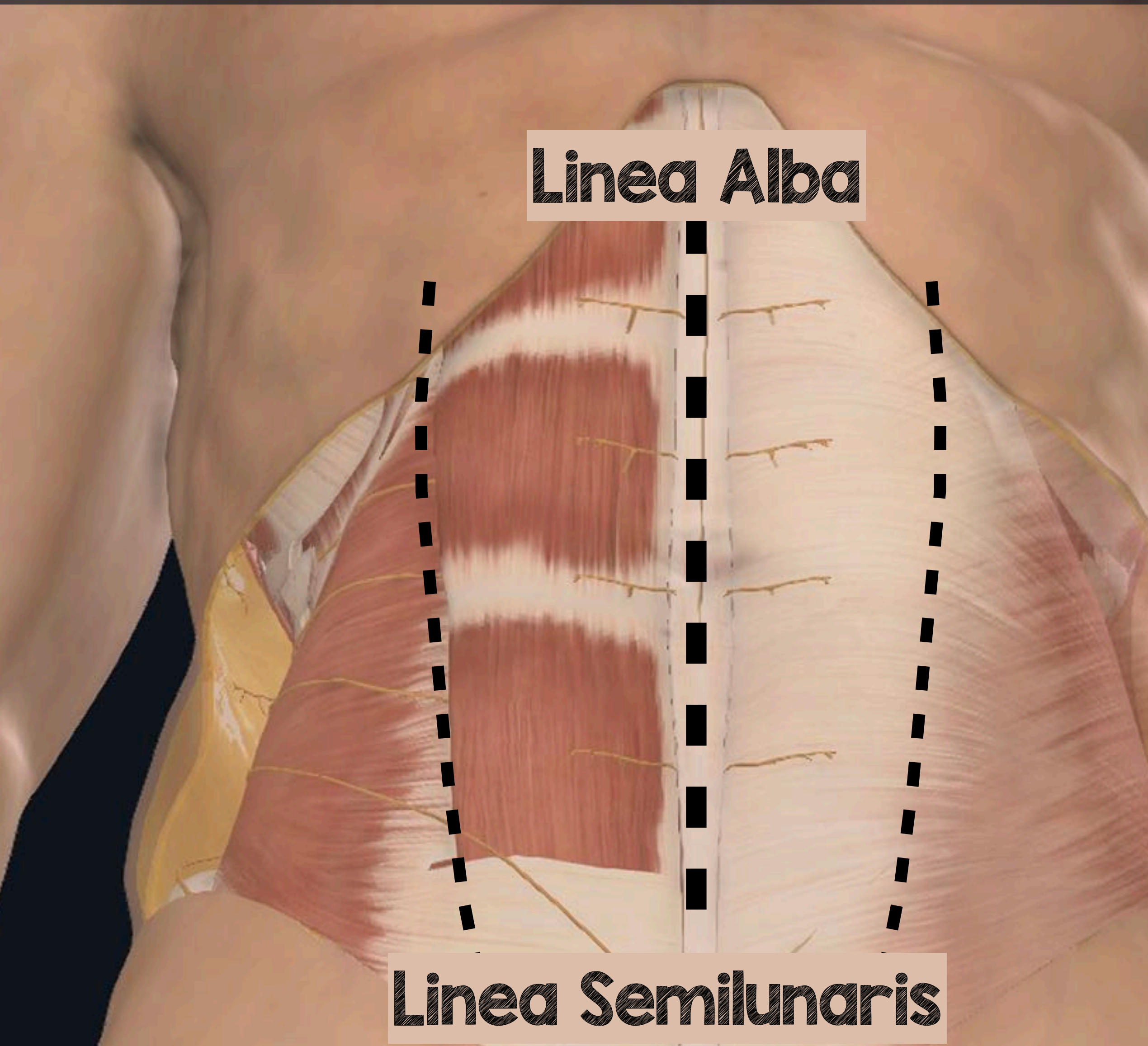




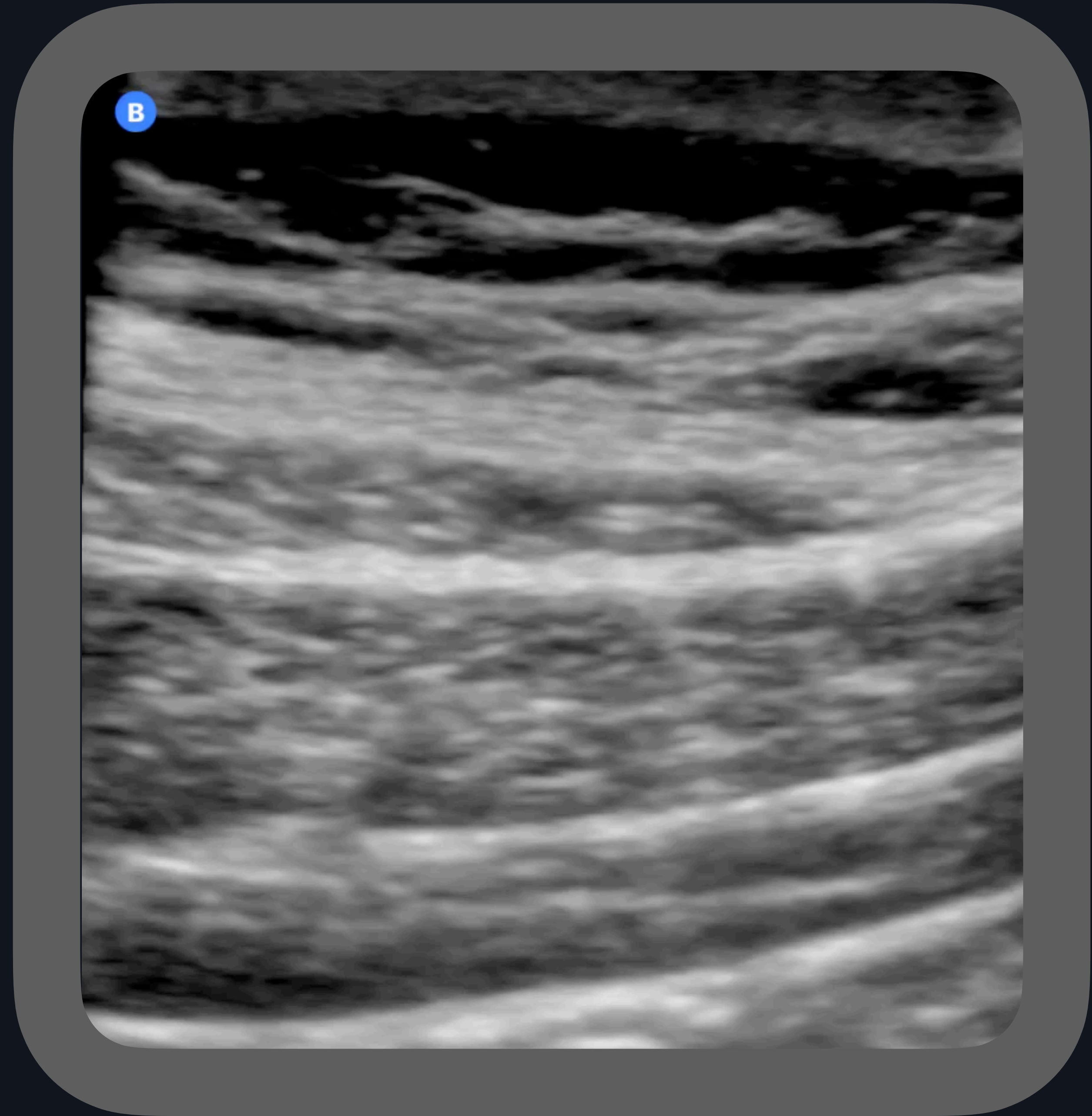
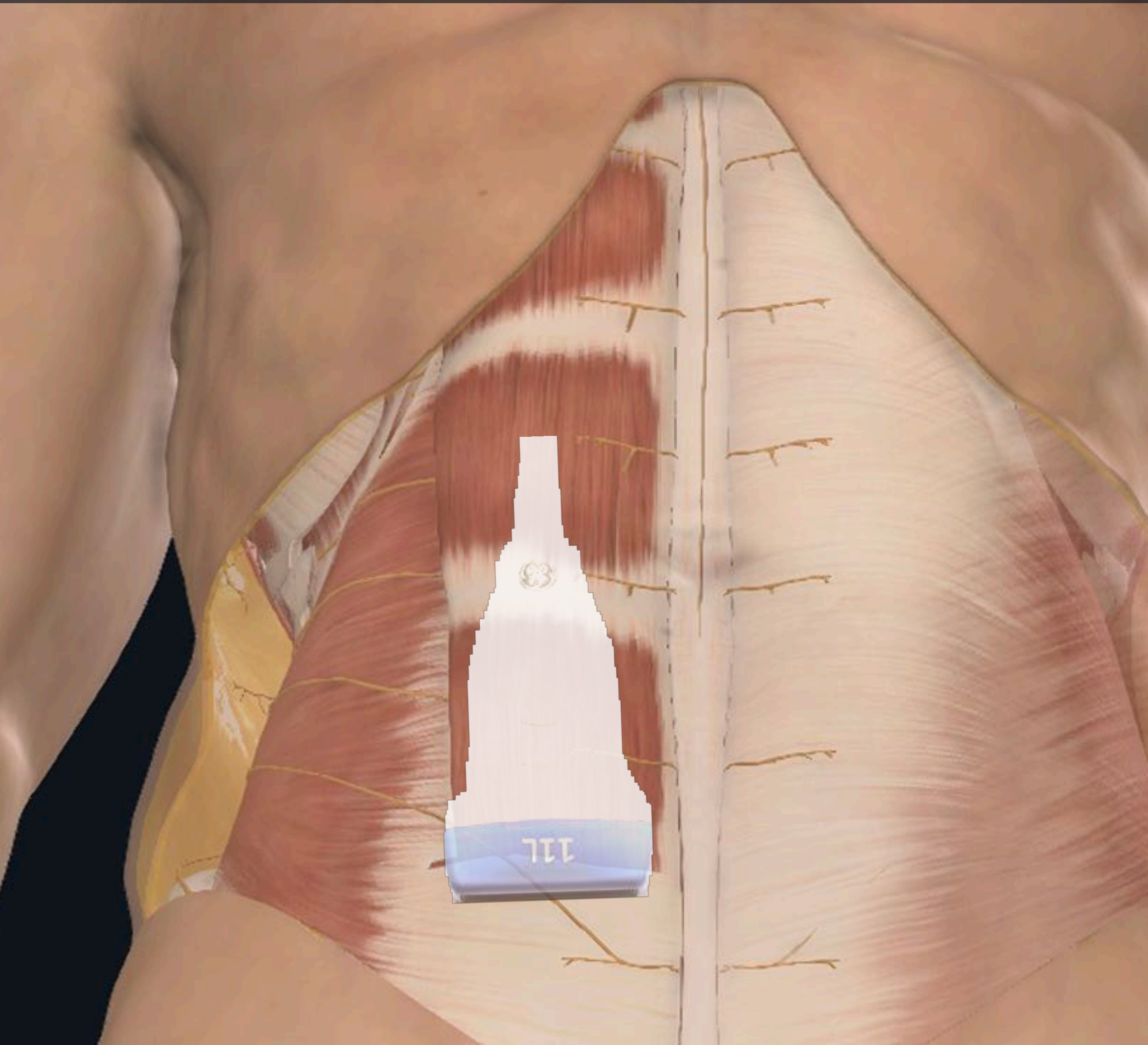
Sono Anatomy



# Sonoanatomy

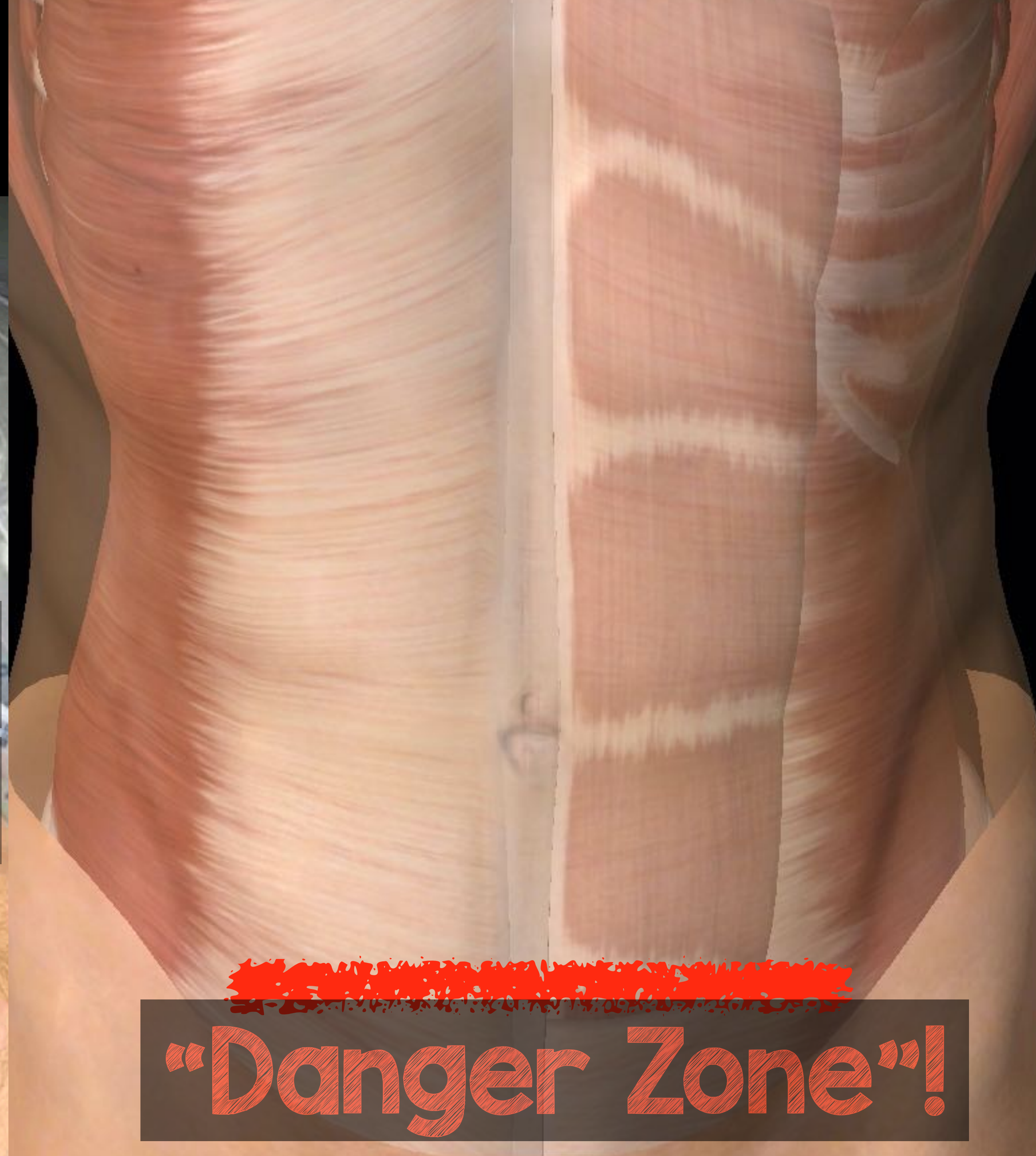


# Sonoanatomy



# Technique

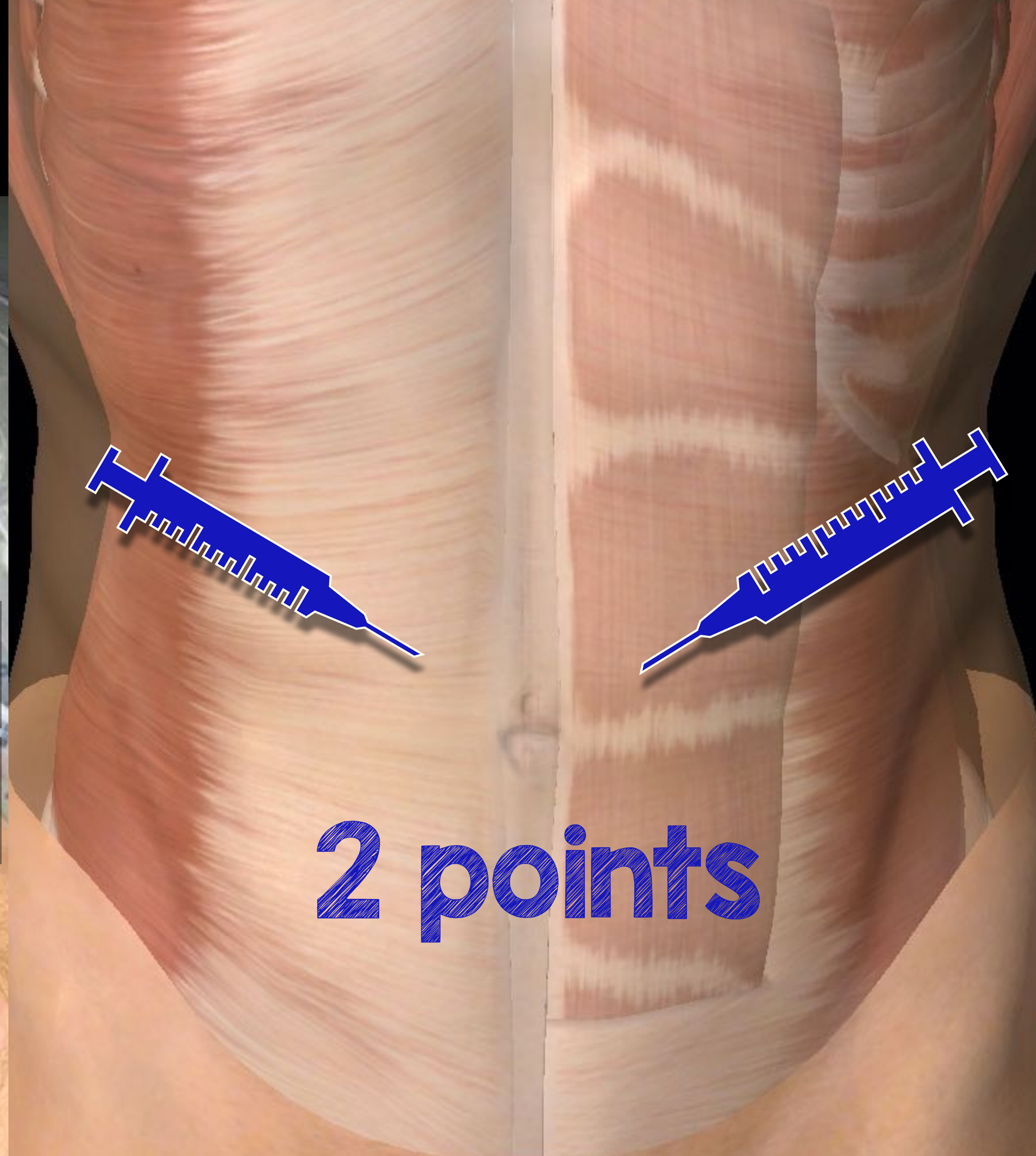
- ✓ Patient Supine
- ✓ Linear Probe
- ✓ Needle In-Plane
- ✓ 10-20 mL LA per side
- ✓ Above "Danger Zone"



**"Danger Zone"!**

# Technique

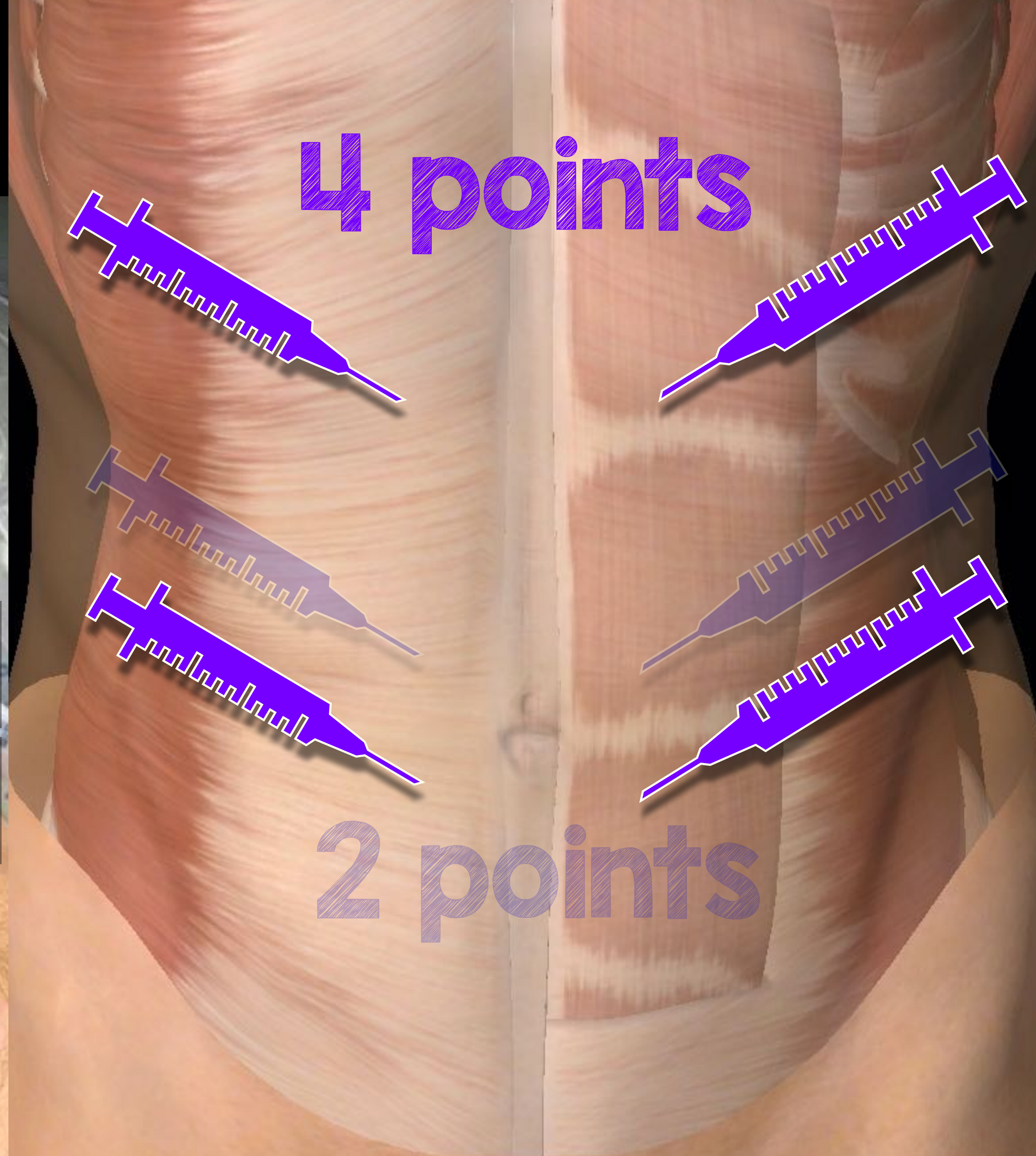
- ✓ Patient Supine
- ✓ Linear Probe
- ✓ Needle In-Plane
- ✓ 10-20 mL LA per side
- ✓ Above "Danger Zone"



2 points

# Technique

- ✓ Patient Supine
- ✓ Linear Probe
- ✓ Needle In-Plane
- ✓ 10-20 mL LA per side
- ✓ Above "Danger Zone"



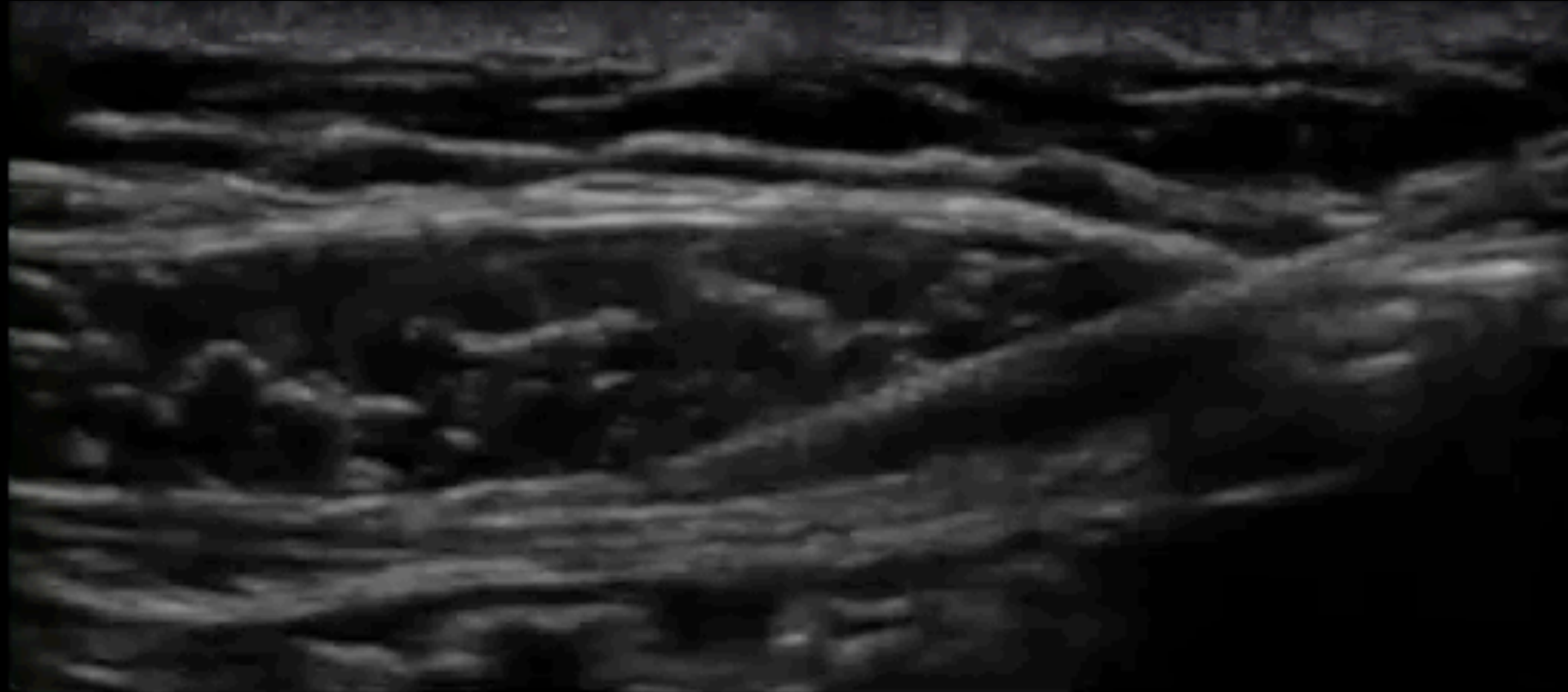
# Technique

- ✓ Patient Supine
- ✓ Linear Probe
- ✓ Needle In-Plane
- ✓ 10-20 mL LA per side
- ✓ Above "Danger Zone"

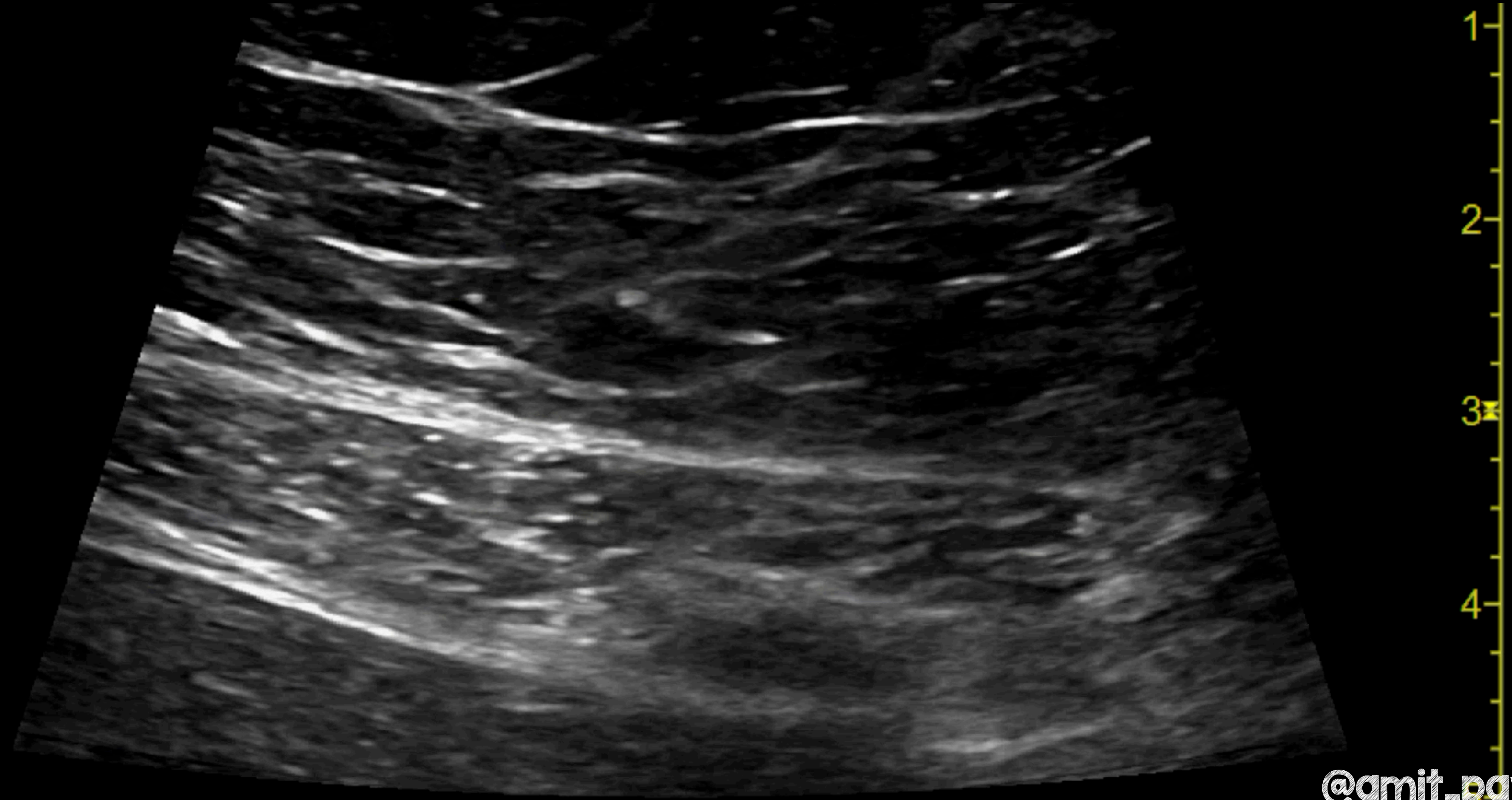
**In an ideal world!**



# The Ideal Block & Patient



# The Less Ideal Patient...



# Tips

Colour Doppler

Pre-Op or Post-Op insertion

Rectus Sheath Catheters

Confirm target by starting from TAP...

Assess Spread by long axis scanning...

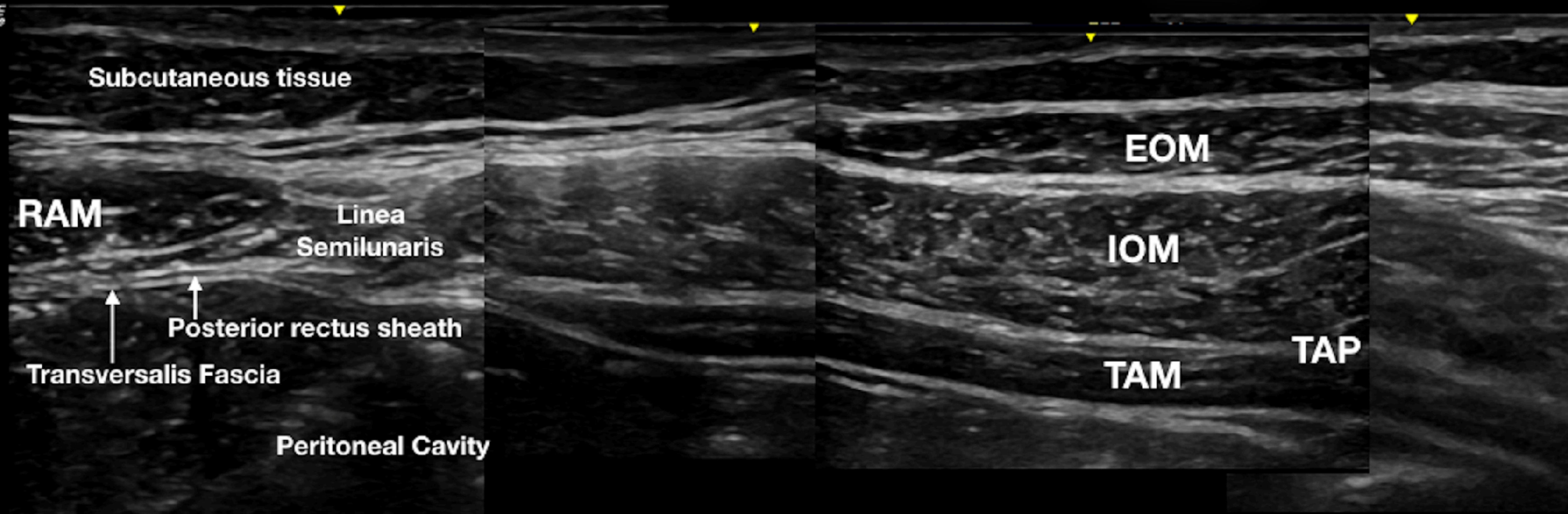
@amit\_pawa

# Scan from TAP...



**MEDIAL**

**LATERAL**



Subcutaneous tissue

RAM

Linea Semilunaris

Posterior rectus sheath

Transversalis Fascia

Peritoneal Cavity

EOM


IOM

TAM

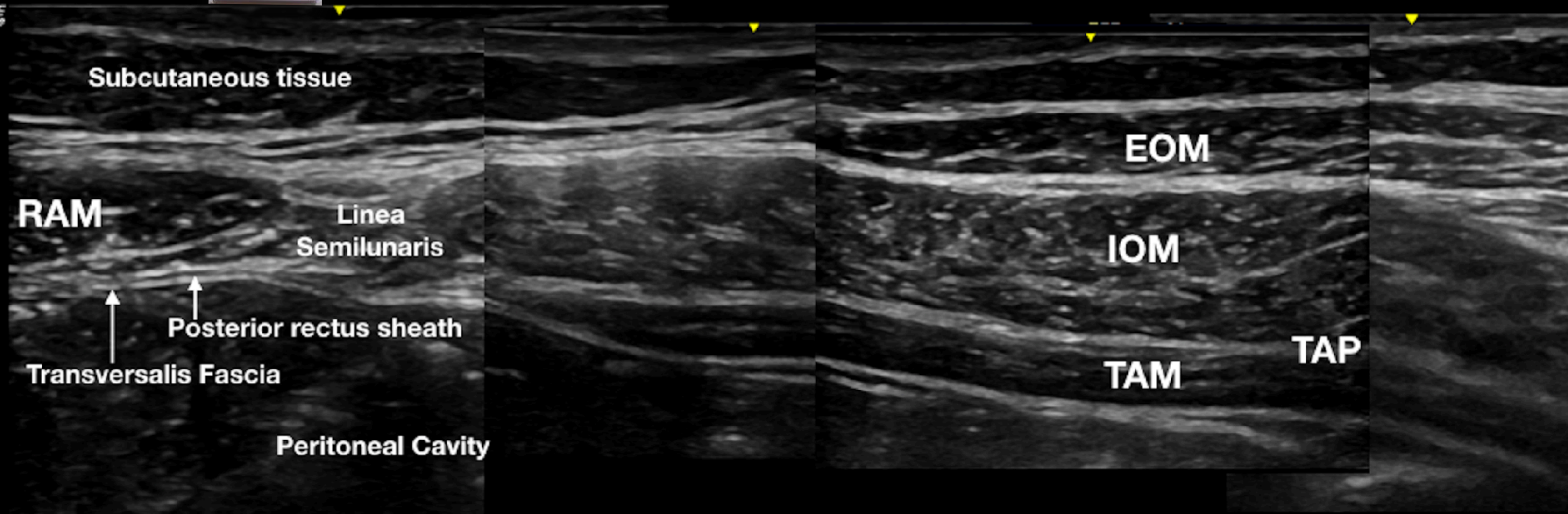
TAP

# Scan from TAP...

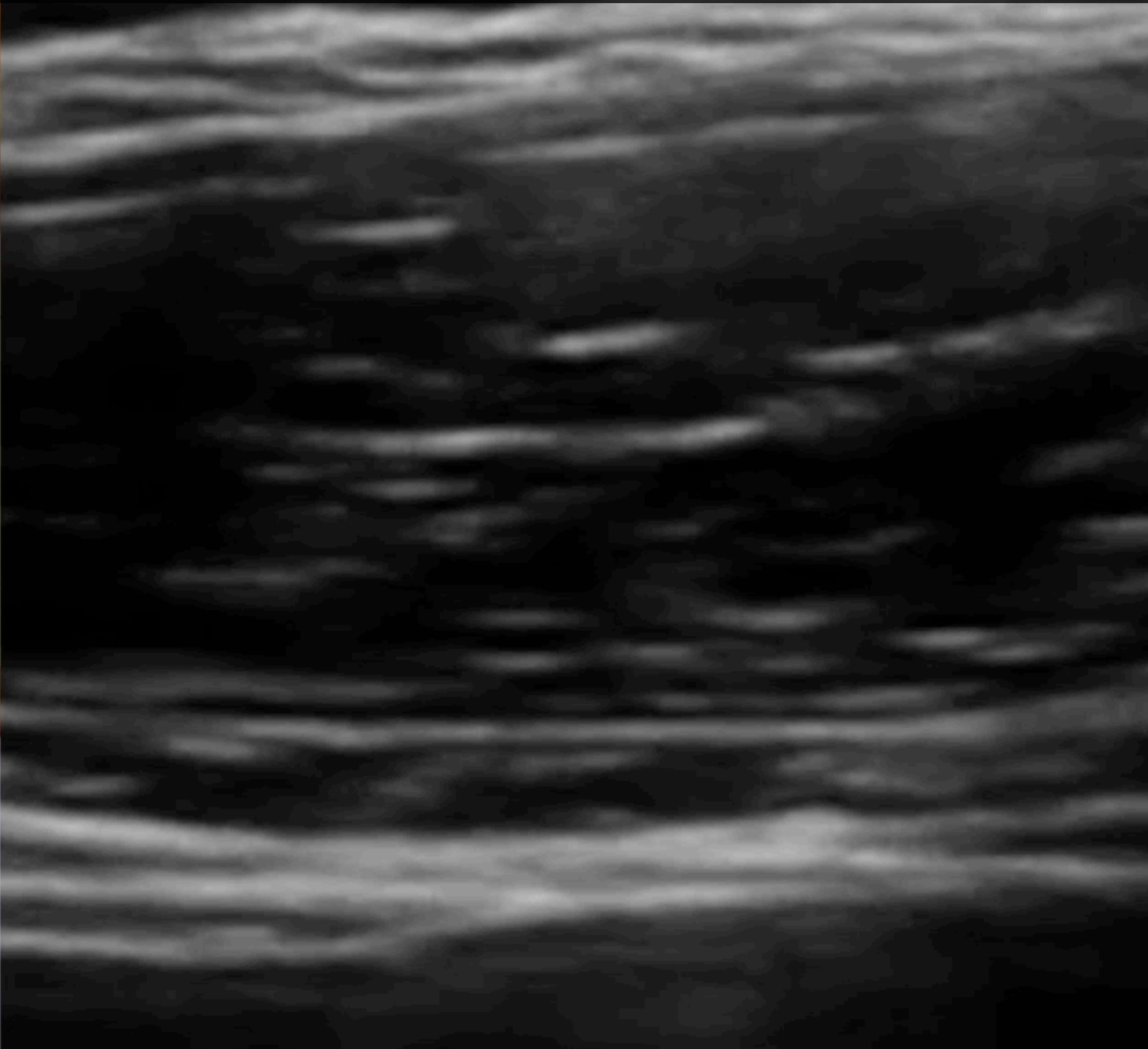
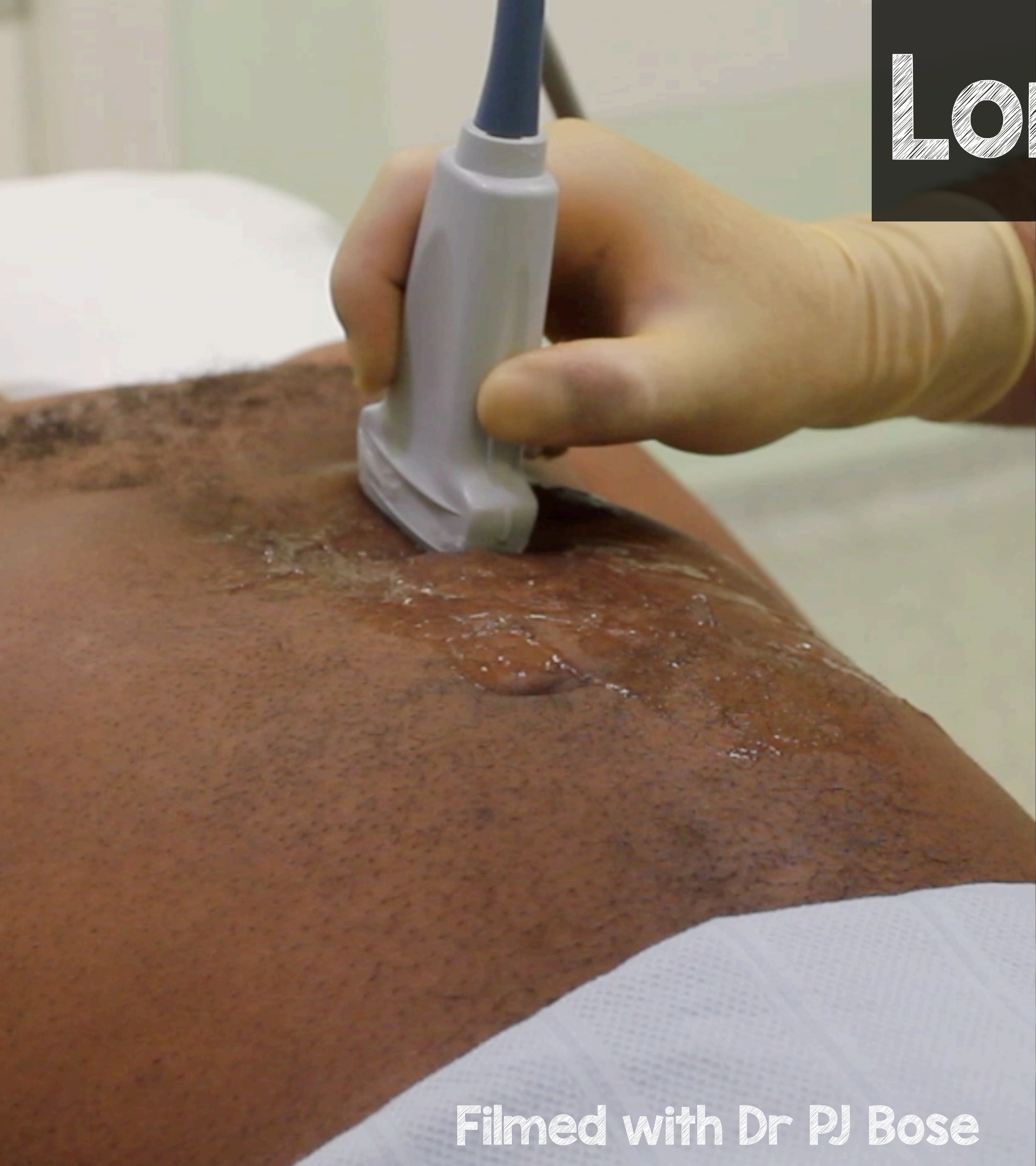MEDIAL



LATERAL



# Long Axis Scanning



Filmed with Dr PJ Bose

# Rectus Sheath Summary

Simple & Safe

Stay above Arcuate Line

RS Catheters for laparotomy

Single shot block in as rescue

**Indications, Anatomy, Technique**

**Rectus Sheath Block**

**Erector Spinae Plane (ESP)**

**@amit\_pawa**



# Erector Spinae Plane (ESP)



Simple

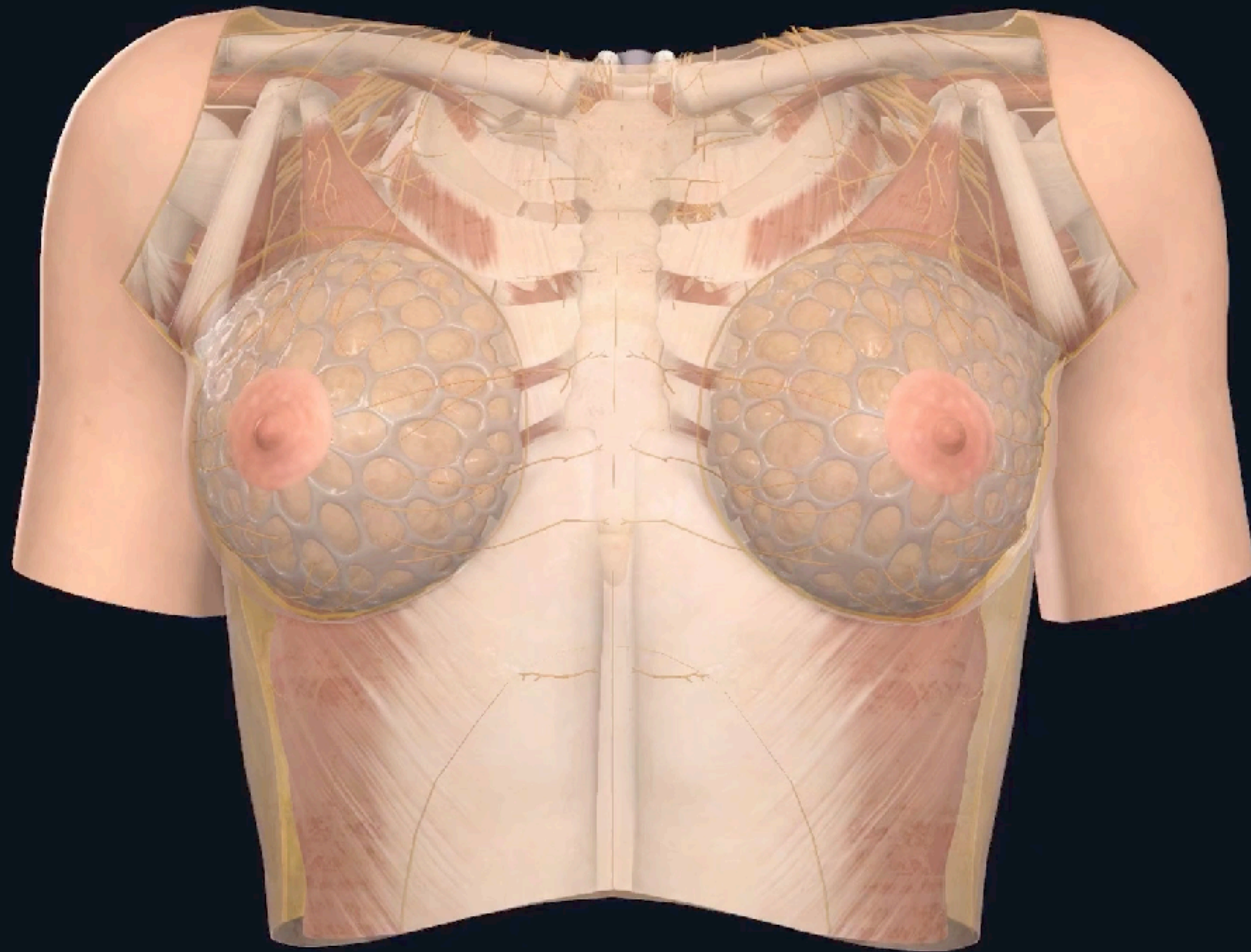


Safe



Versatile

# Indications: Chest Wall Procedures



**Breast** At T4-5  
**Thoracic** Level  
**Rib Fractures**  
(Abdo/Spine/Hip)



# This Choice Caused some Controversy!

**Why Not Thoracic Epidural ?**

**Why Not Thoracic Paravertebral?**

**Why Not Serratus Plane Block?**

ESP

Similar principle to Serratus

Shallow Learning Curve

Teachable

Versatile

Low Risk

@amit\_pawa

# Erector Spinae Plane

Skin of the Back

Trapezius

Rhomboid

Erector Spinae

TP

TP

TP

PVS

PVS

PVS


Lung

# Erector Spinae Plane

Skin of the Back

Trapezius

Rhomboid



Lung

Erector Spinae

Not "One"  
Muscle

# ESP Anatomy

Trapezius  
Rhomboids

ESM

TPs

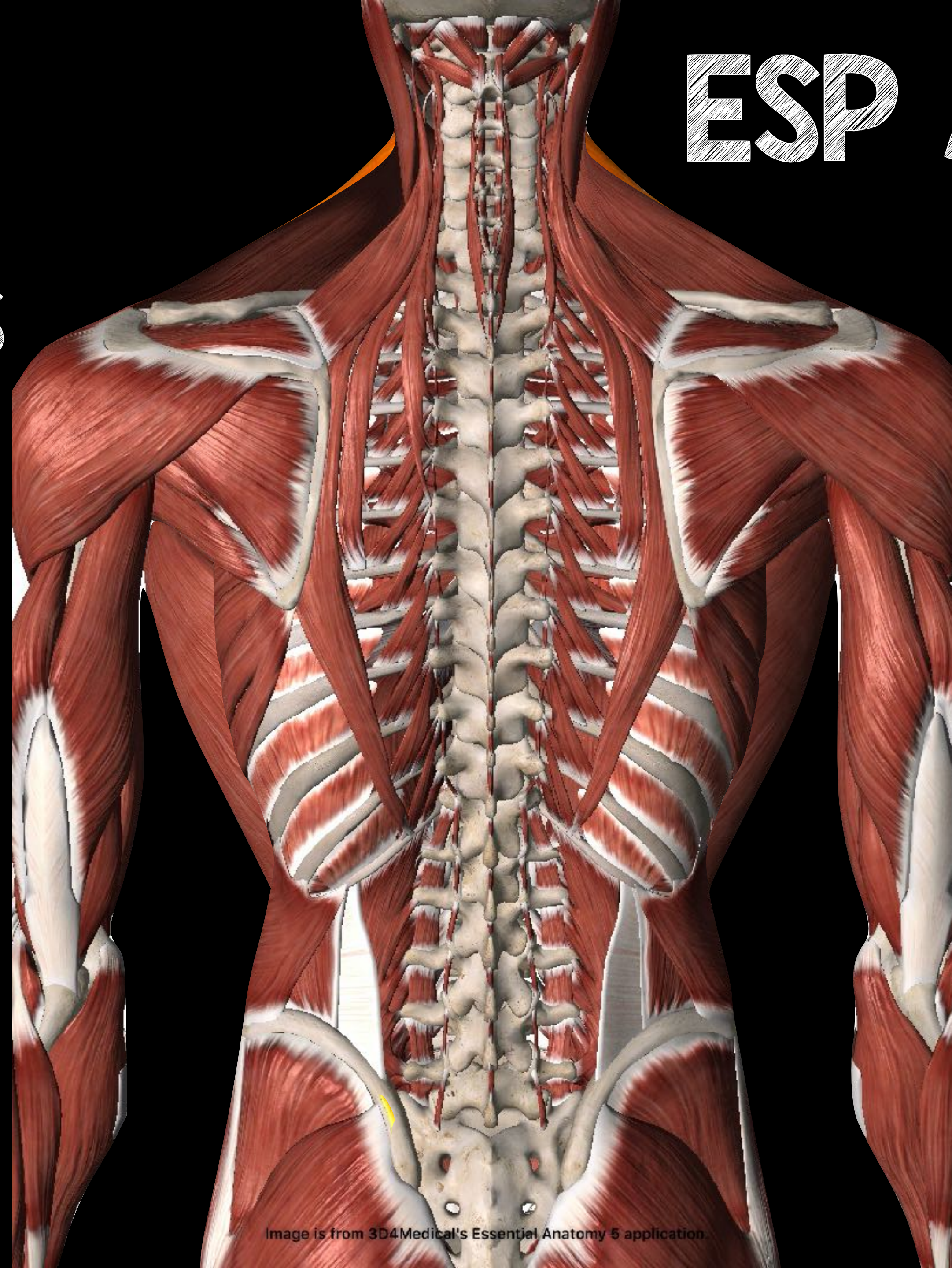
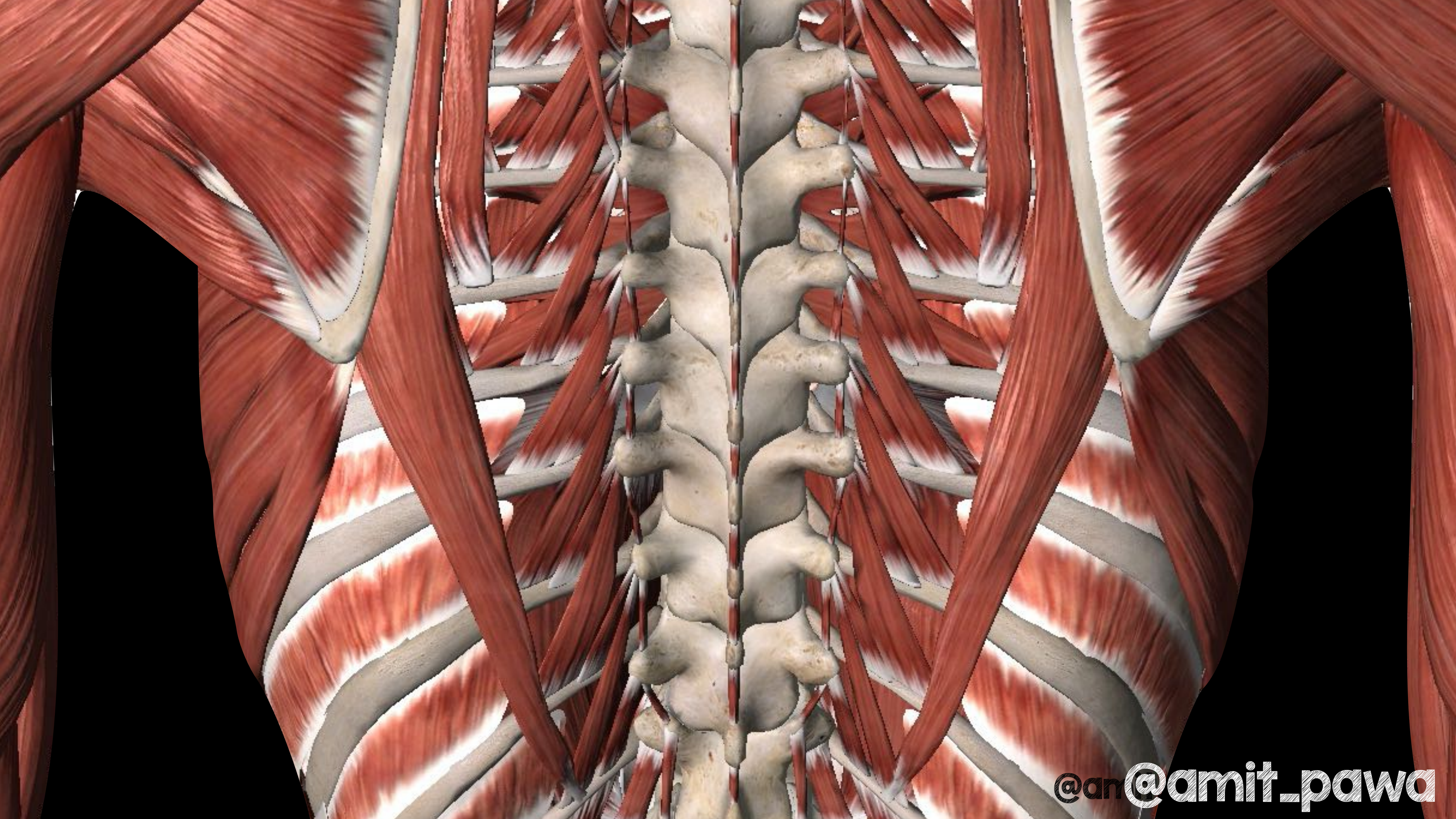


Image is from 3D4Medical's Essential Anatomy 5 application.

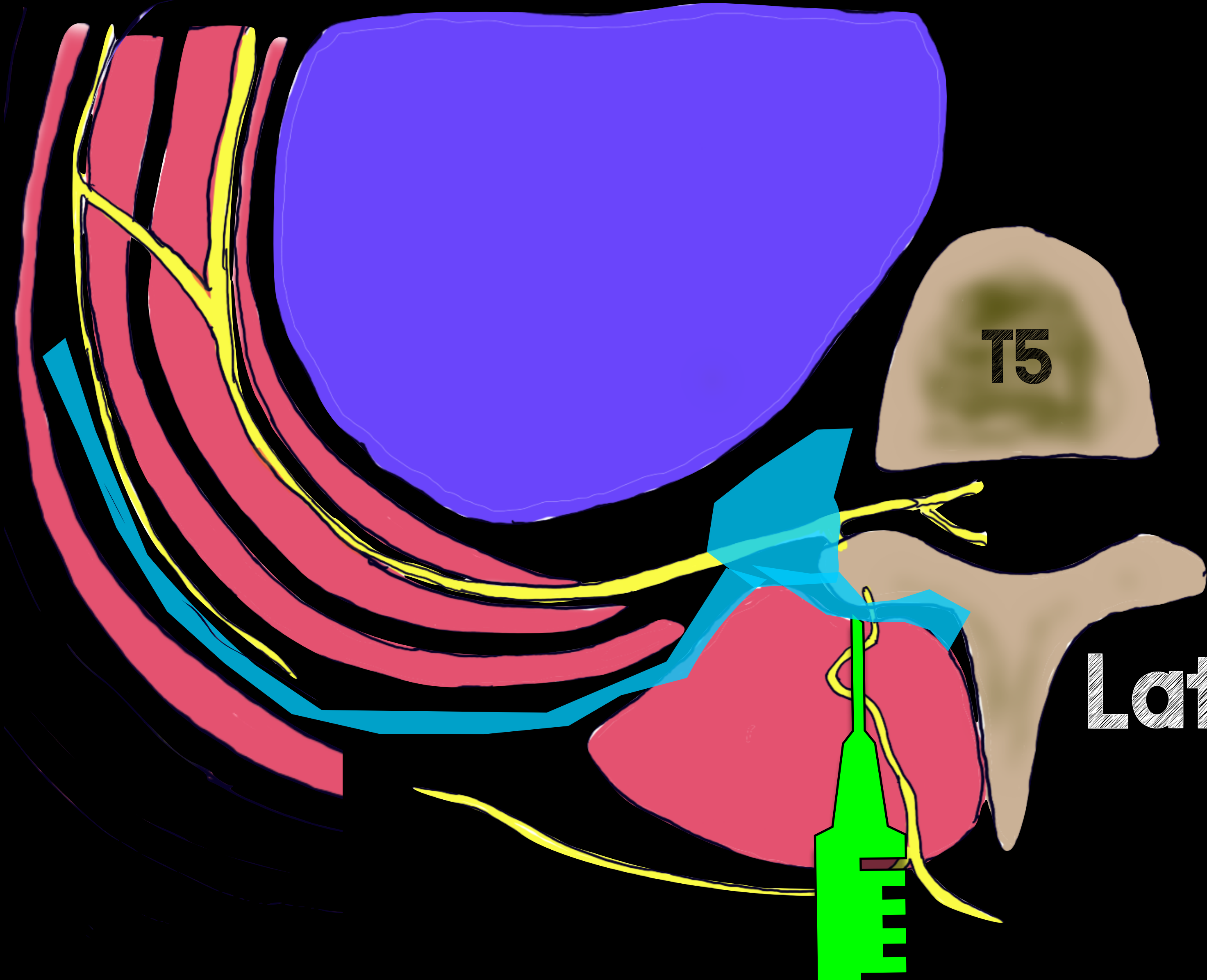
@amit\_pawa



@an@amit\_pawa

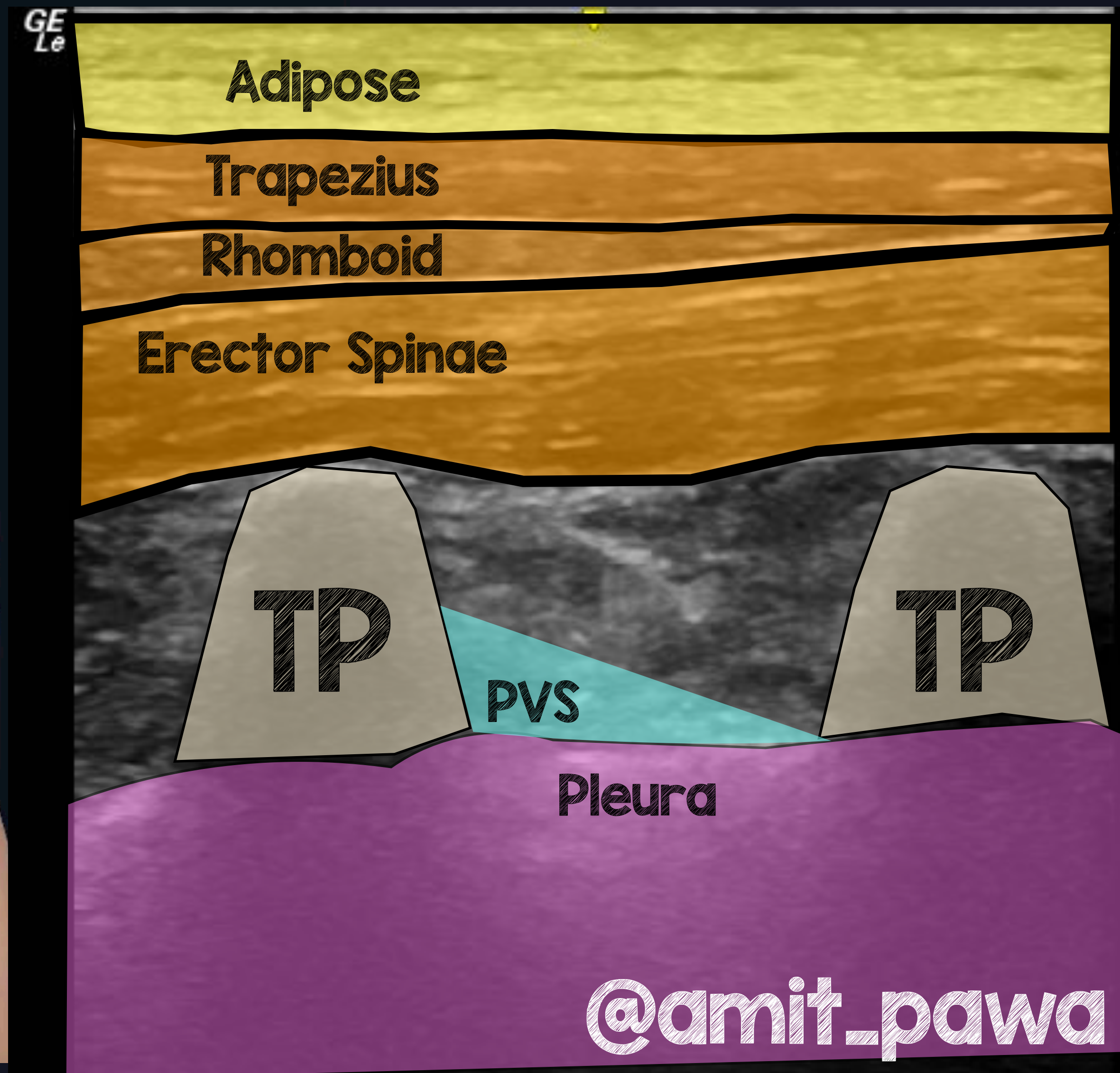
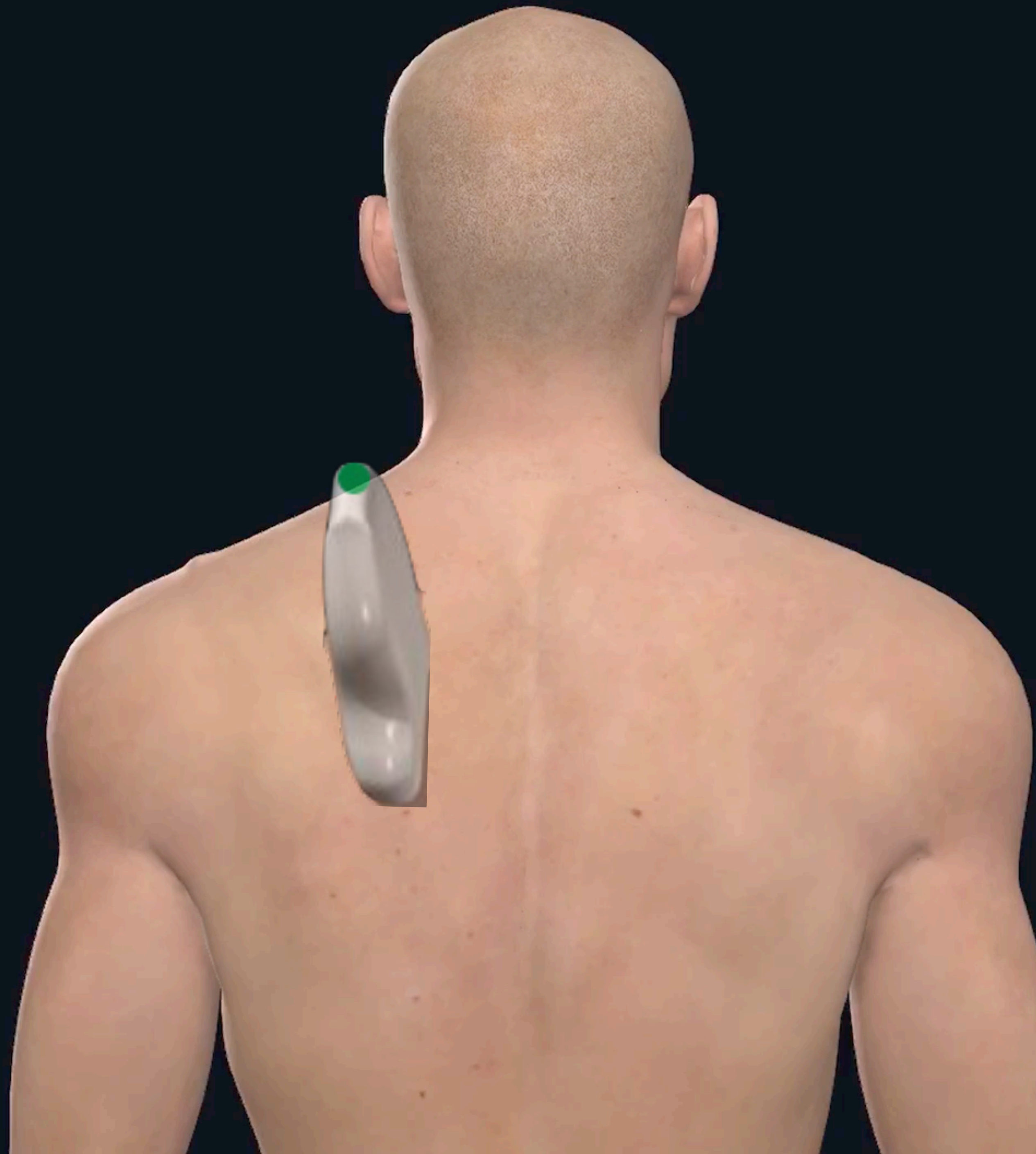


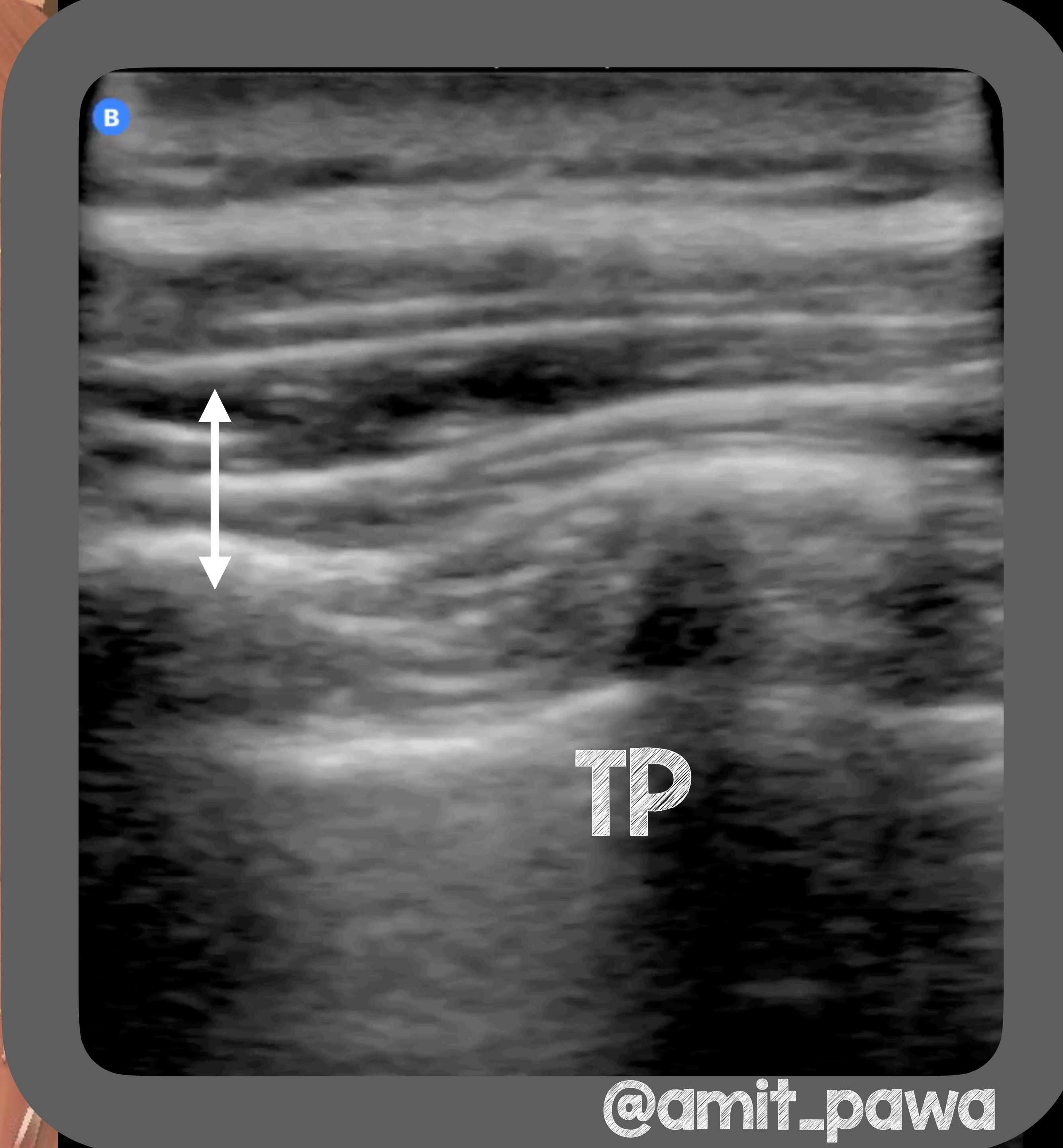
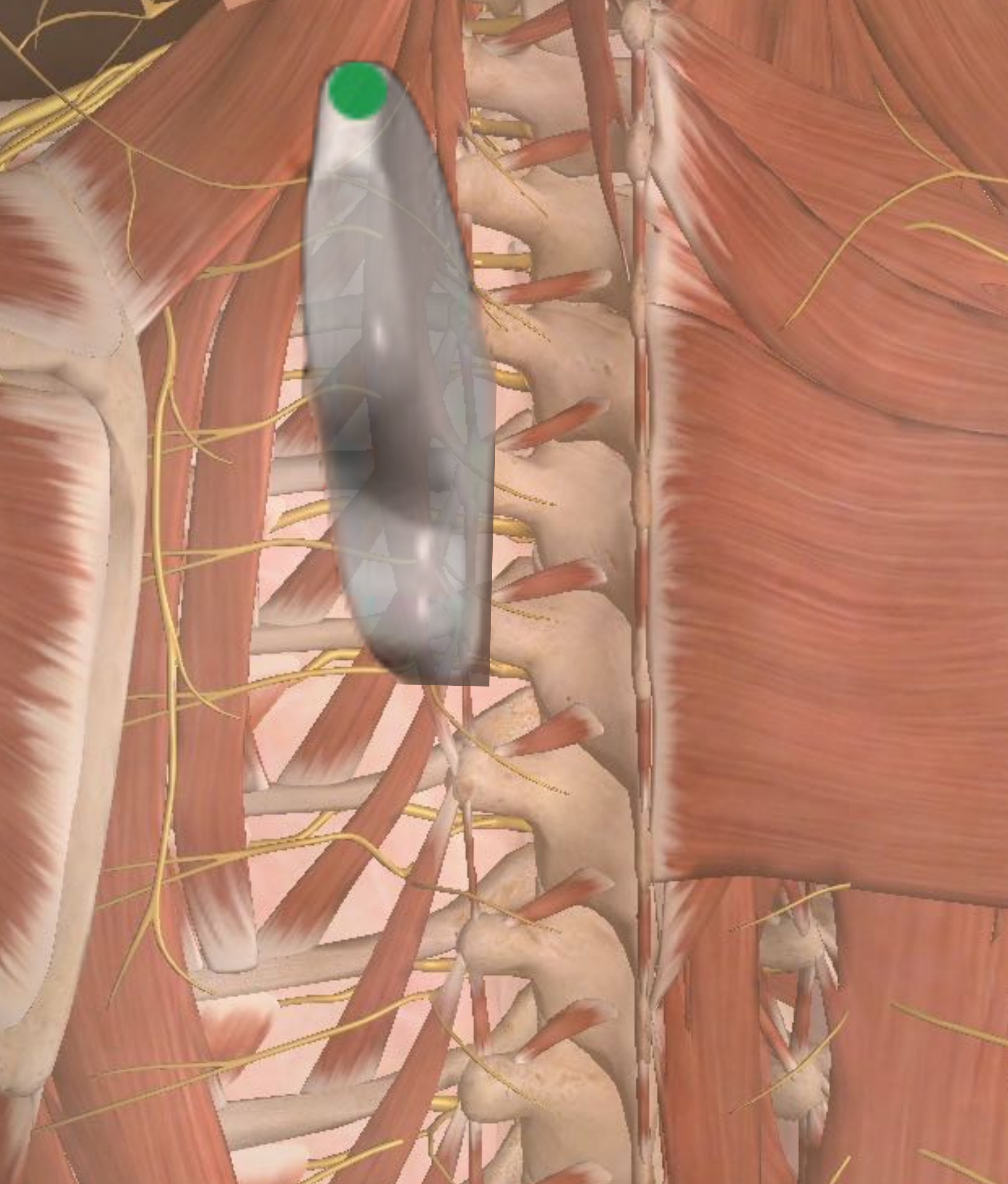
# ESP - Mode of Action?..



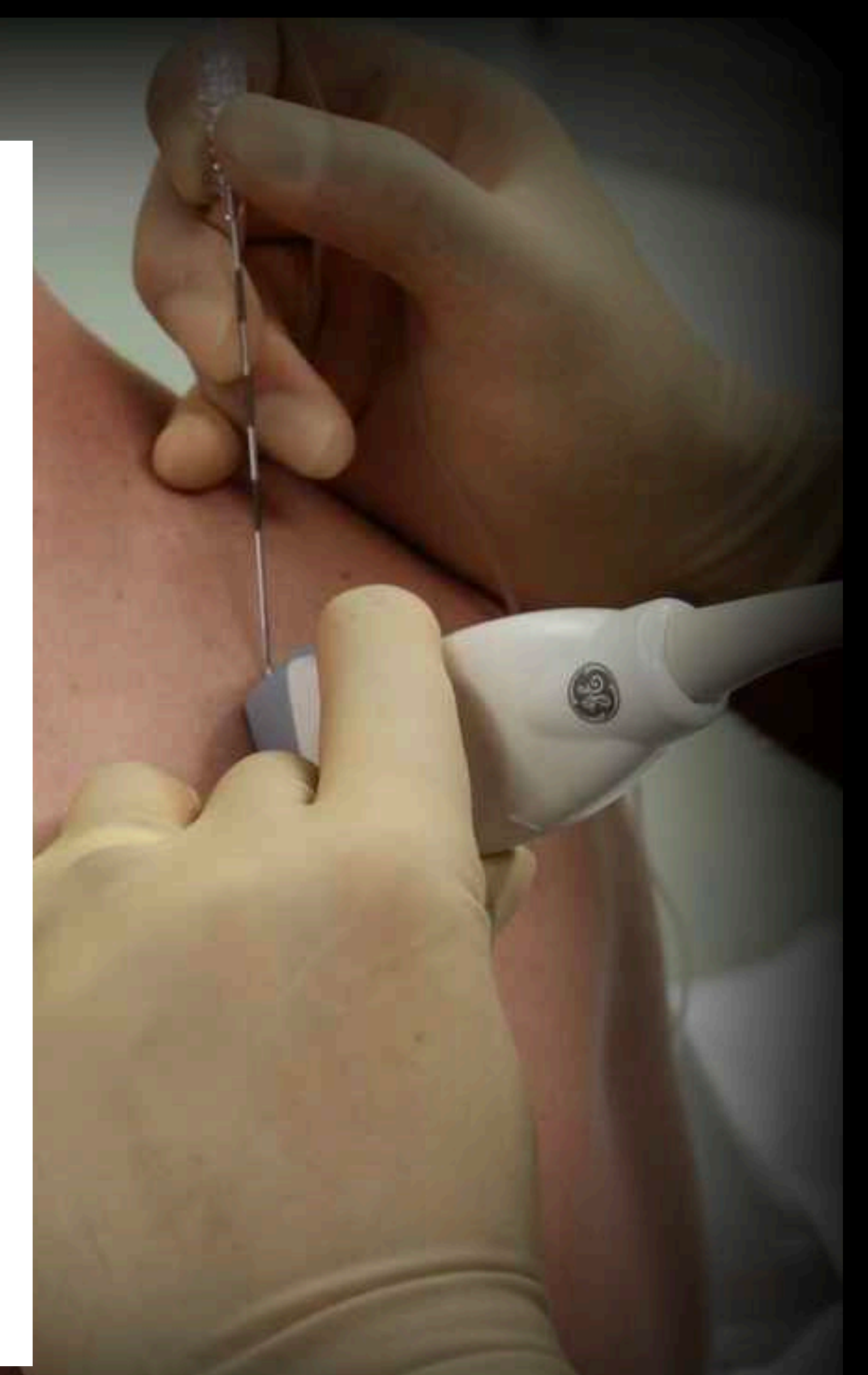
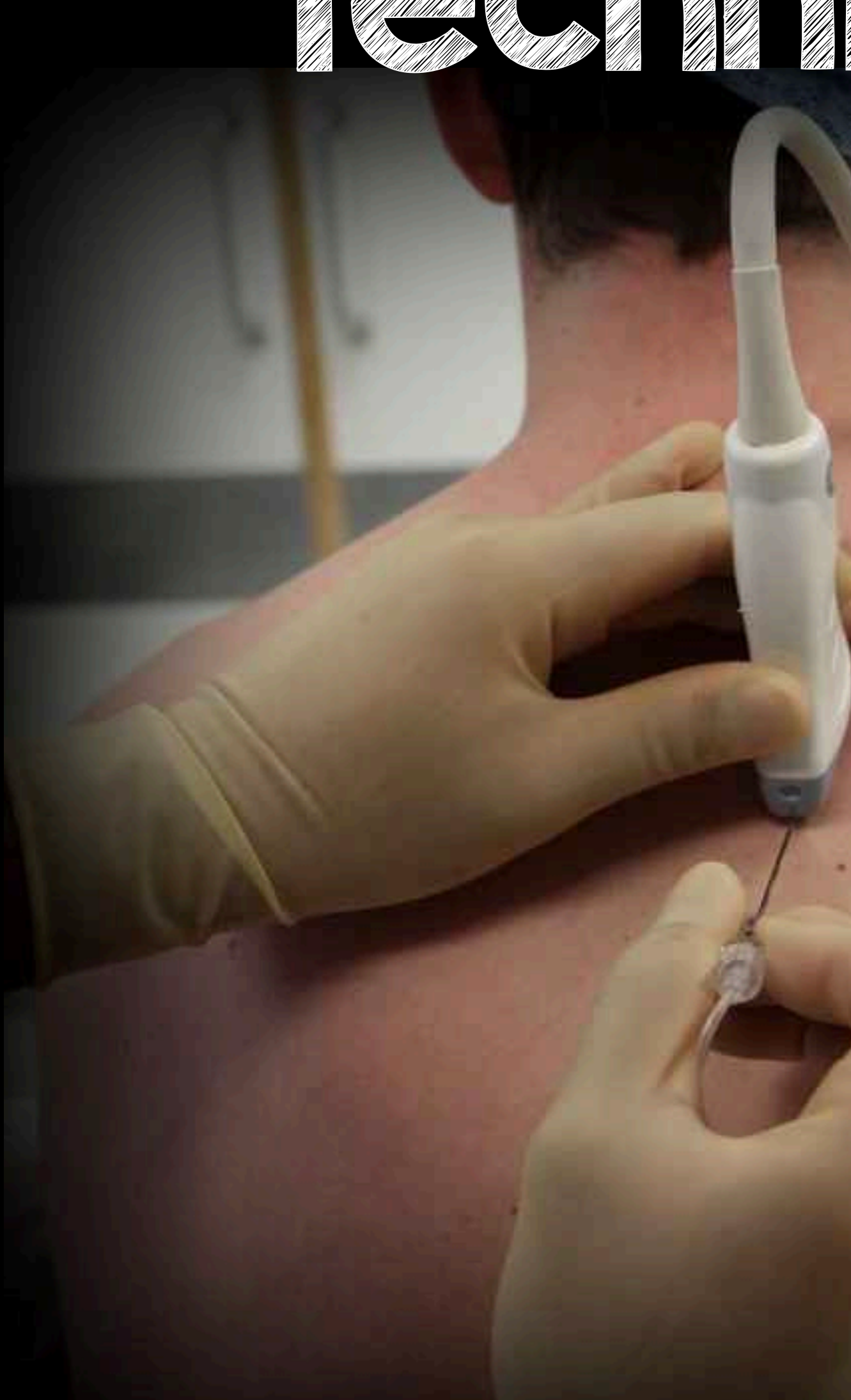
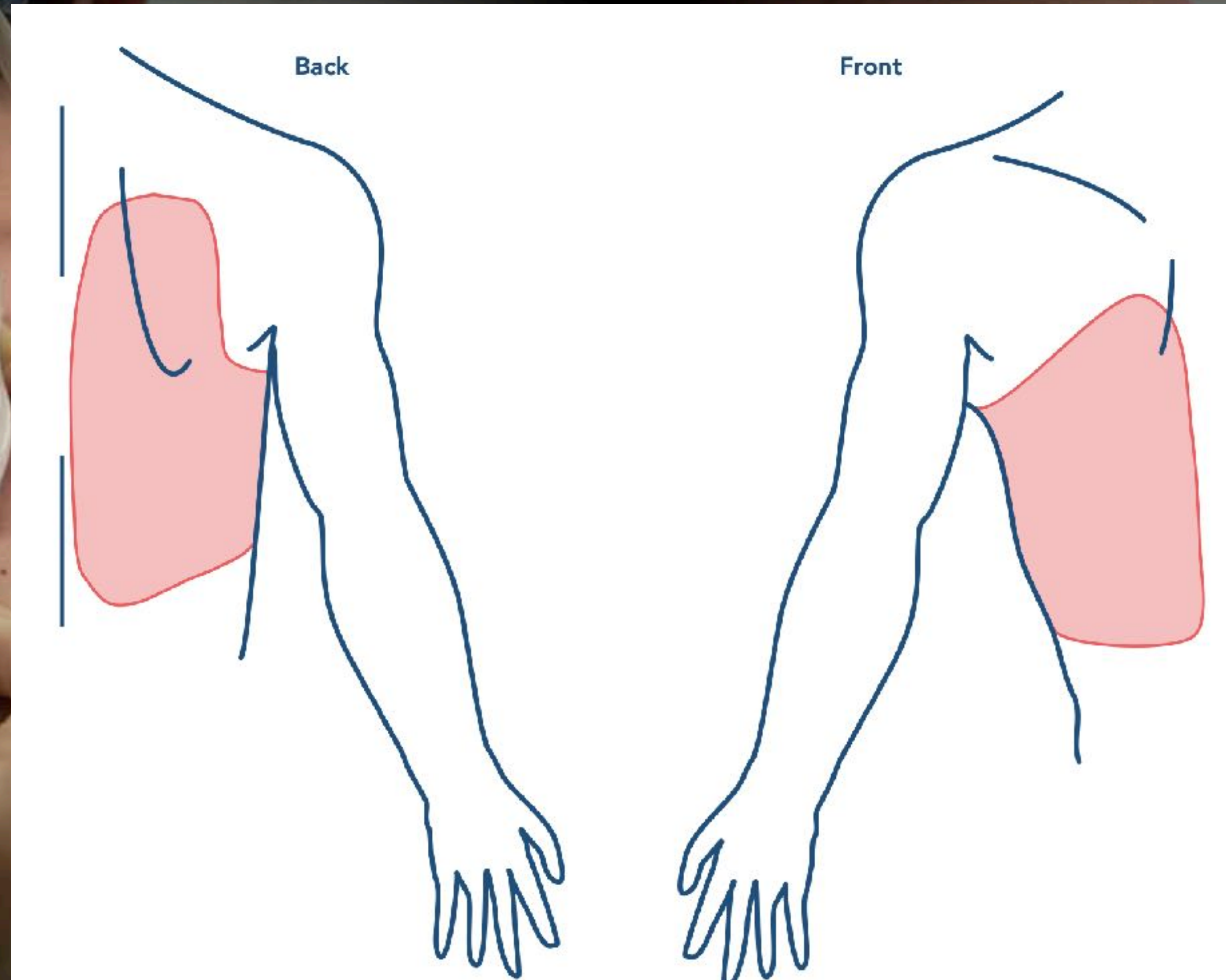
PV by Proxy?  
↑  
Ventral Ramus?  
Dorsal Ramus  
Lateral Cut branch?  
↓  
Serratus by Proxy?

Sono anatomy





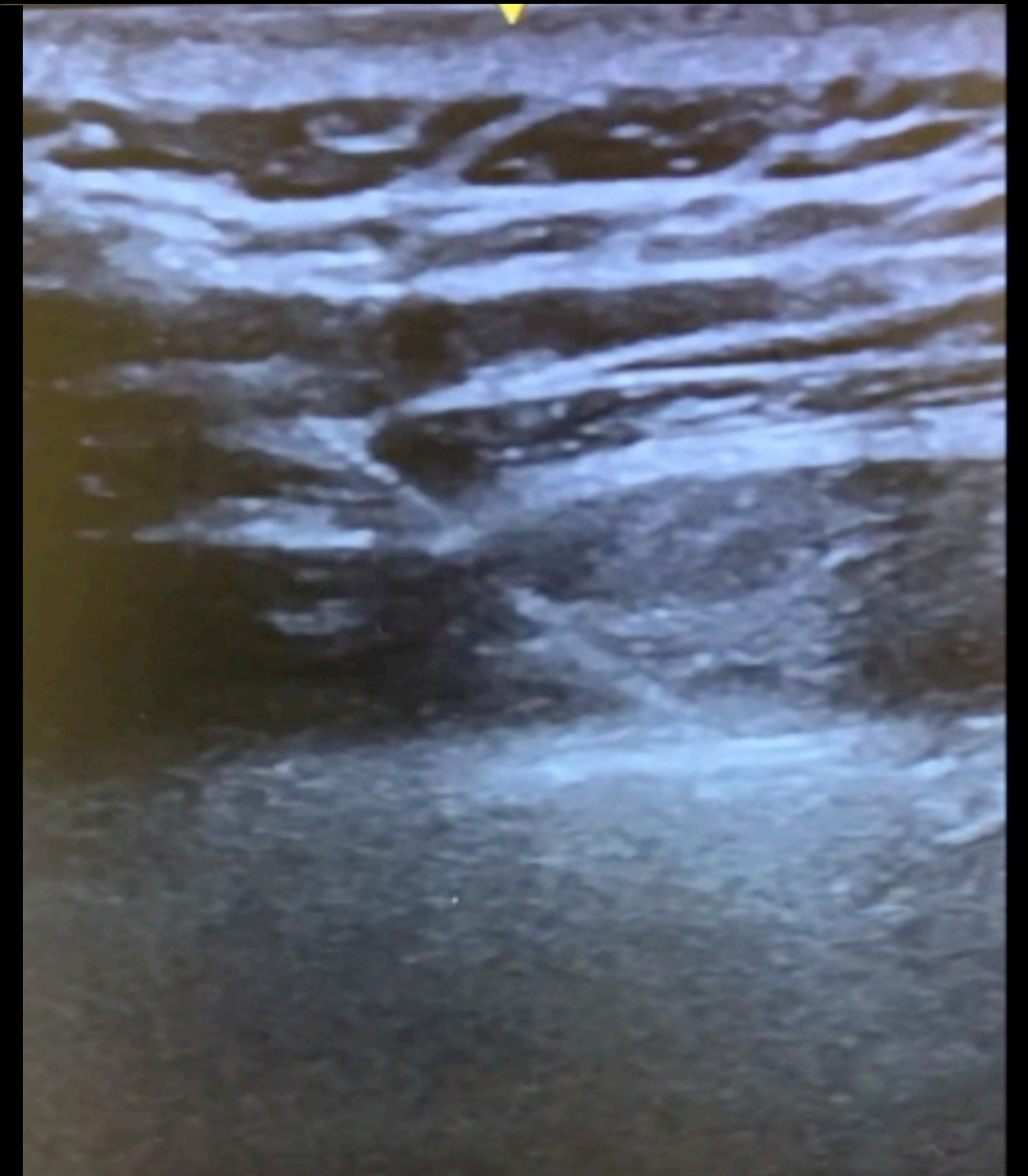
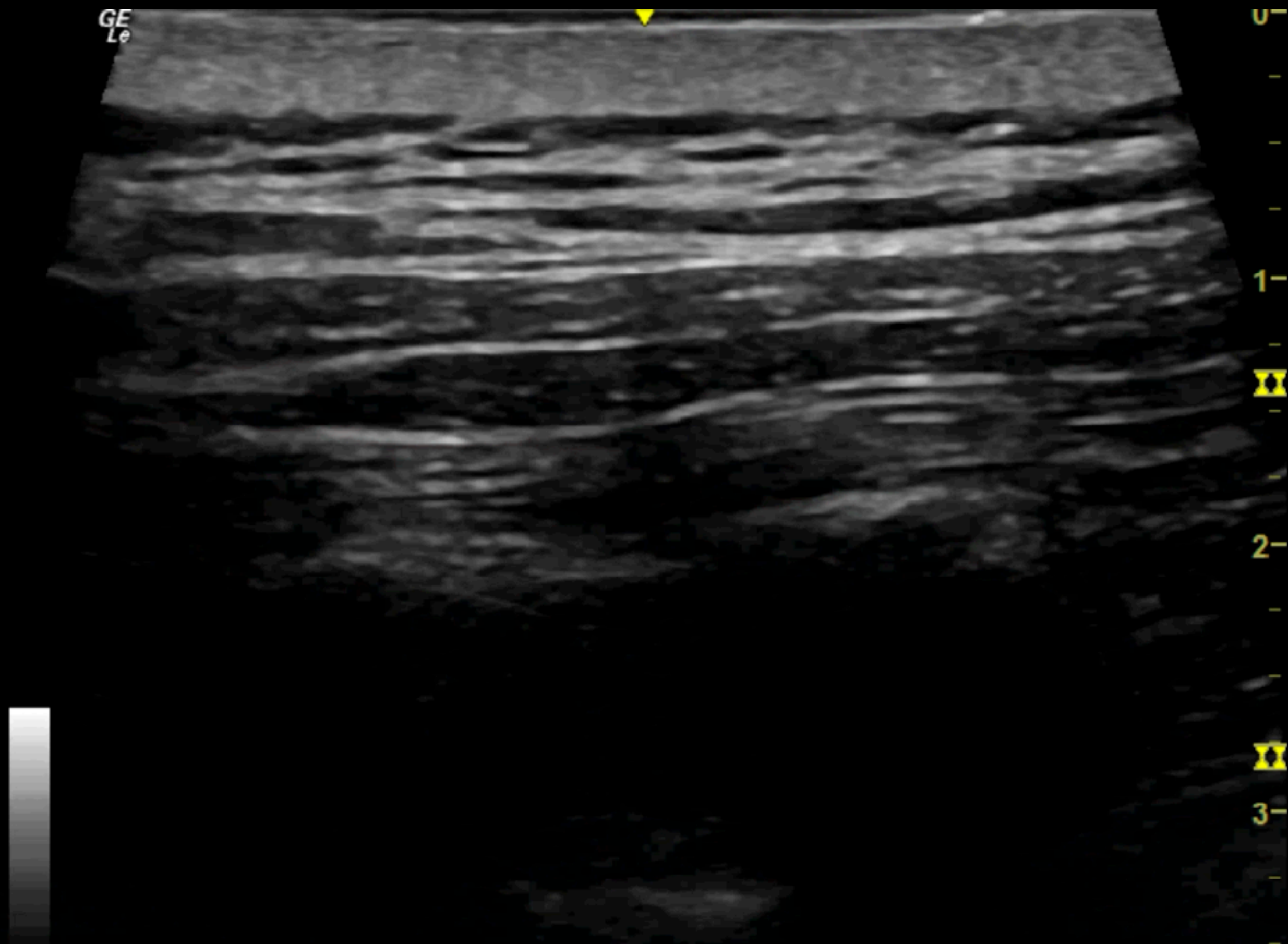
# Technique



**Ideal dermatomal coverage?**

# ESP Block Examples

# ESP Block Videos



# Tips

Use a "Seeker Solution" (don't waste LA)

Volume Block - (dose of LA)

Successful block has "Black Stripe of LA"

ESP Catheters



# Tips

Use a "Seeker Solution" (don't waste LA)

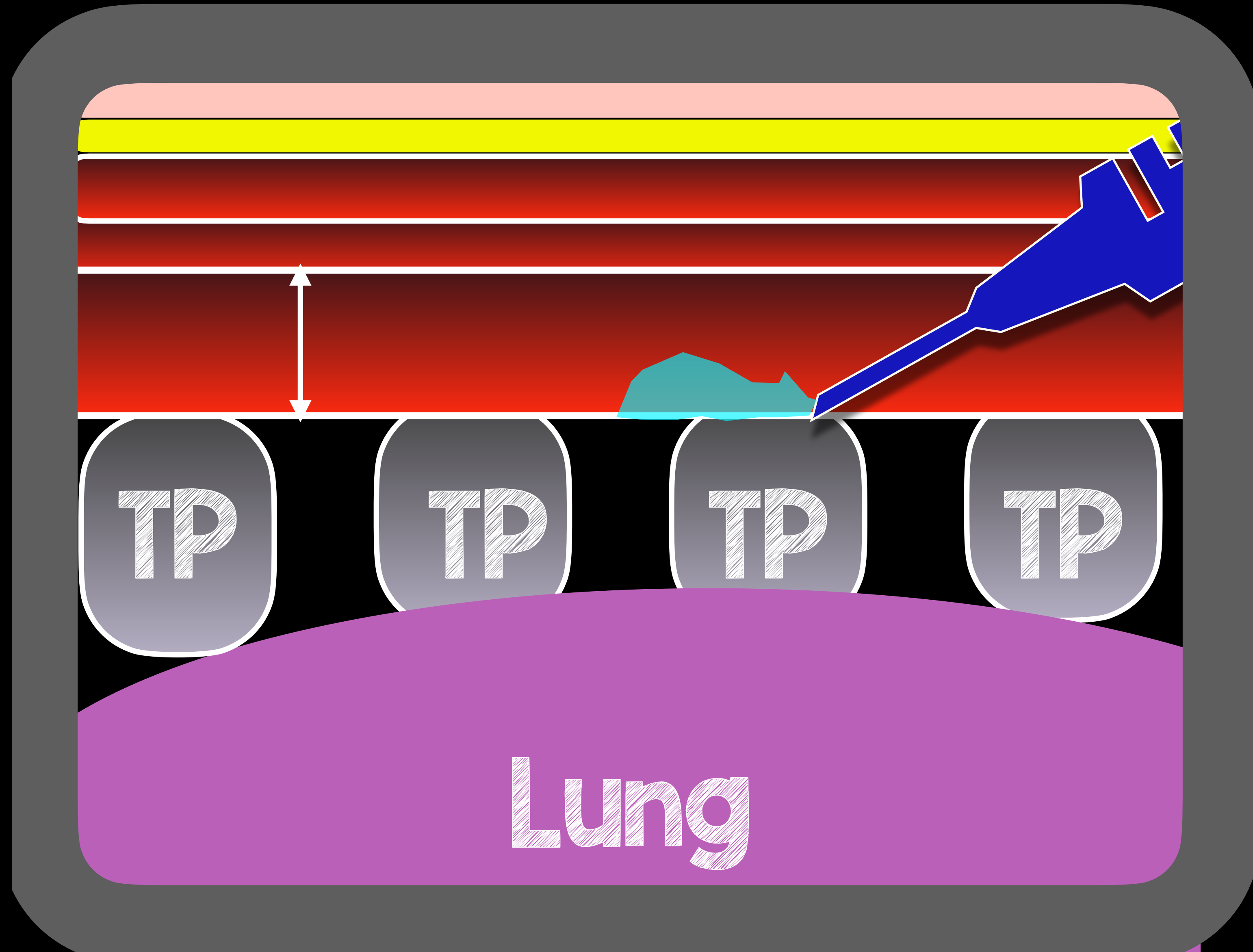
Volume Block - (dose of LA)

Successful block has "Black Stripe of LA"

ESP Catheters

Aim for Tip/Corner of TP...

# Finding The right plane

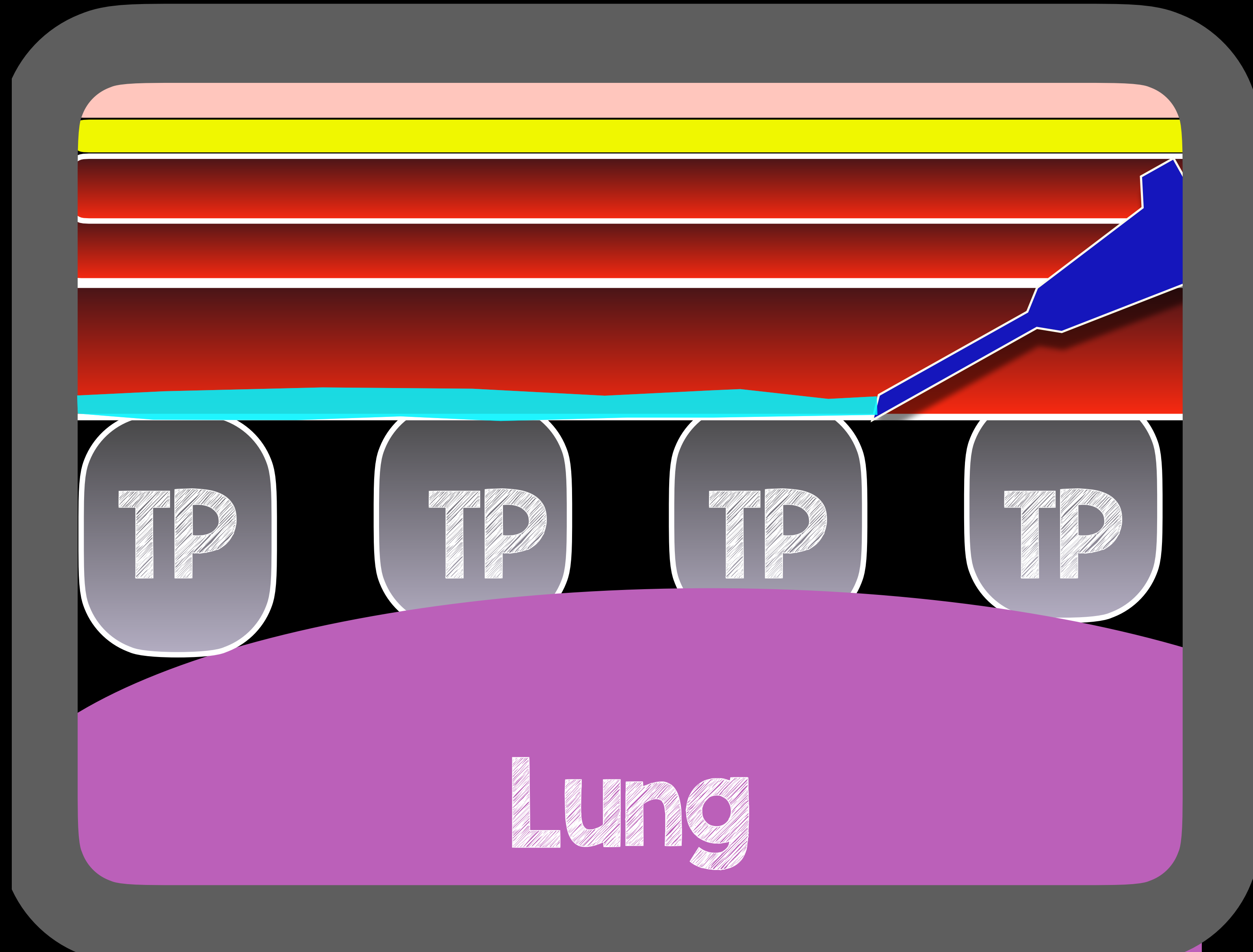


Aiming for  
top of TP...

I/m  
injection

@amit\_pawa

# Finding The right plane



Aiming for  
Corner of TP  
"Stripe" of LA  
"Pulsatile" Flow

# Summary

# Summary

**New Block - many potential indications**

**Evidence of Safety & Efficacy coming**

**Easy to perform**

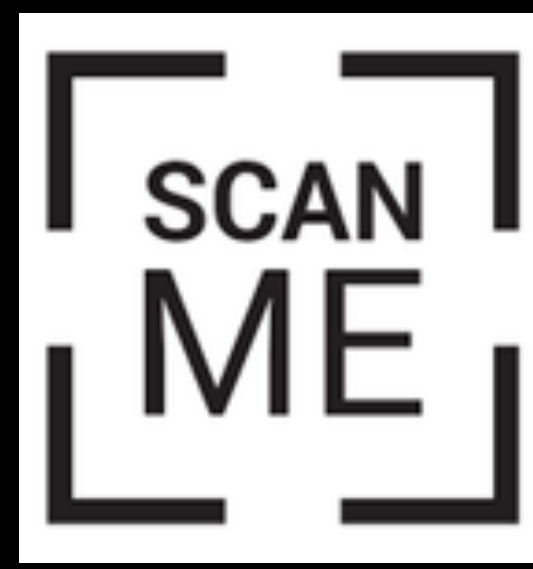**Can be performed Pre/Post Op**

**Avoids Epidural "issues"**

**Stepping stone to Paravertebral Block**

**@amit\_pawa**

# Reading List



**RAUK - Plan A Blocks**



**BJA Ed Article - rectus sheath**



**#Blocktober - Rectus**

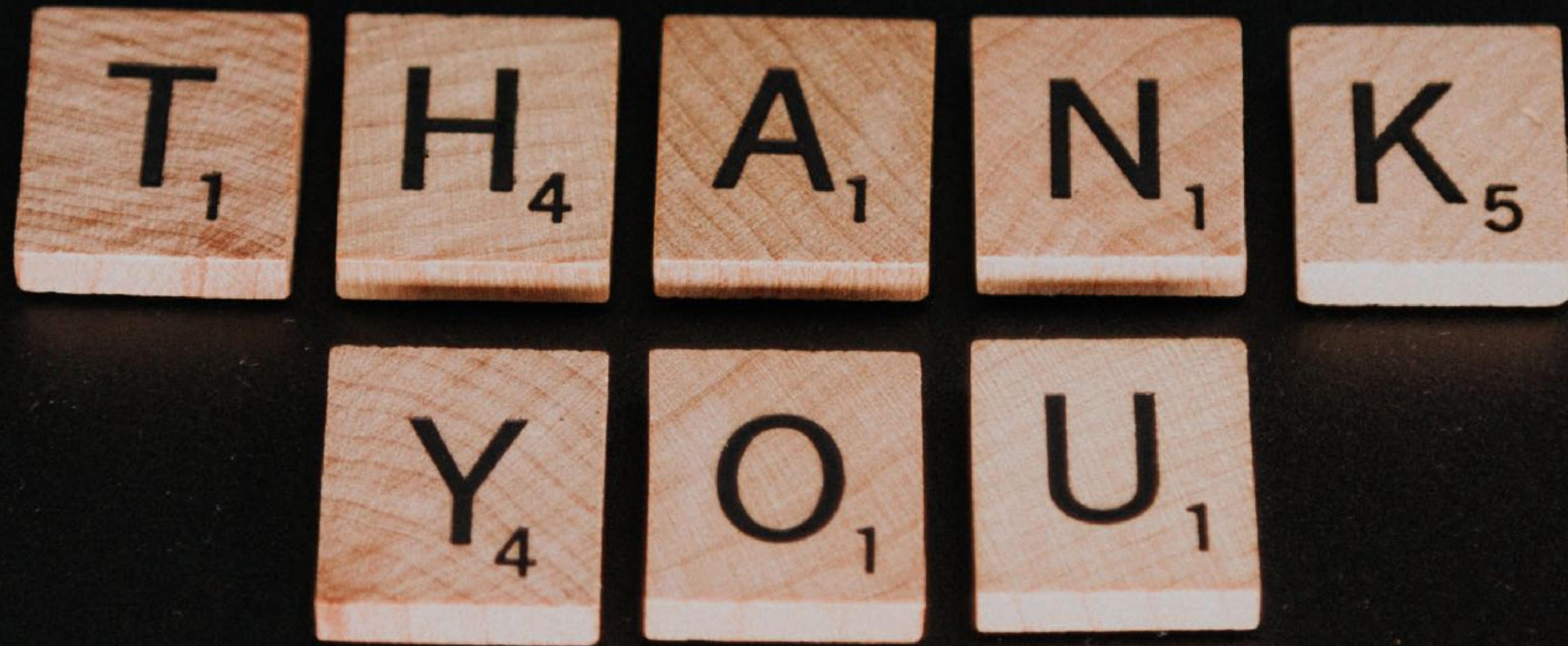

**#Blocktober - ESP**



**ASRA news - ESP**





T<sub>1</sub>

H<sub>4</sub>

A<sub>1</sub>

N<sub>1</sub>

K<sub>5</sub>

Y<sub>4</sub>

O<sub>1</sub>

U<sub>1</sub>

